The Benchmark Laboratory Manual

for

Emergency Medicine

Eighth Edition
2012

Ernest Ruiz, MD
Professor Emeritus

Revised By
Carol Peterson, RN
Richard Gray, MD

The University of Minnesota & Hennepin County Medical Center are committed to the policy that all persons shall have equal access to its programs, facilities and employment without regard to race, color, creed, religion, national origin, sex, age, marital status, disability, public assistance status, veteran status or sexual orientation.

Preface
This Benchmark Skills Laboratory provides an opportunity for emergency physicians, physician's assistants, nurse practitioners, nurses, and other emergency personnel to refine and practice skills as a team, in an educational setting that is realistic but non-threatening.

Acknowledgements
This manual is based on the work of Ernest Ruiz, M.D. founder of the Department of Emergency Medicine at the University of Minnesota Medical School. This eighth edition was edited/ revised by Carol Peterson, R.N. and Richard Gray, M.D. and includes the latest science of emergency procedures.

The editor wishes to thank the dedicated clinicians who contributed to its review and revision.
Ann McIntosh, M.D.
Daniel O'Laughlin, M.D.
Gordon Rockswold, M.D.

This project was completed with the additional help of the following people:

Joseph Clinton, M.D., Professor and Head, Department of Emergency Medicine, University of Minnesota Medical School and Chief of Emergency Medicine, Hennepin County Medical Center;

Darrell Carter, M.D., CALS Program Director, for the revision of the Obstetrical Emergencies section;

Norma Heuer, R.N., CALS Instructor for formatting and editing assistance;

Kari Lappe, R.N., CALS Program Manager;

Peggy Lundberg, Veterinarian Technician, Emergency Department, Hennepin County Medical Center;

Mary Ann McNeil MA, EMT-P, Director, Department of Emergency Medicine, University of Minnesota Medical School;

Paula Chambers, R.N., Trauma & Critical Care Services, Hennepin County Medical Center;

Karie Pearce, R.N., Trauma & Critical Care Services, Hennepin County Medical Center.

Financial Statement
The procedure methodologies and equipment have been found to be safe and effective in this setting in the hands of practitioners with a wide range of experience in emergency procedures. No endorsement of any product is intended beyond this statement. The laboratory and its instructors have no financial interest in the products used.

Disclaimer
The procedures taught have been successfully performed in the lab by teams with varied backgrounds. Most have been successfully performed as described in clinical emergency situations. This is a lab manual. For references and more details, please read textbooks, such as *Clinical Procedures in Emergency Medicine*, edited by Roberts JR and Hedges JR, published by W.B. Saunders Company, Philadelphia.

While animal models are invaluable for teaching and learning invasive procedures, direct extrapolation to human medicine is not always possible. The laboratory experience alone should not be considered a credentialing mechanism.

Educational Credits
Continuing educations credits will be awarded by each facility based on their policy and procedure.

Curriculum
This course consists of one-on-two instruction of physicians (team leader role) and one-on-two instruction of nurses (team member role) in a series of procedures closely following the technical description of procedures in this manual. Most procedures are based on a clinical scenario described by the instructors.

Setting
Procedures are performed “in the emergency department in a small rural hospital” covered by the team. In a sense, this is “white knuckle cockpit training” as practiced by the airlines. An EMT ambulance delivers critical cases of all kinds.

Objectives
The teams attending an eight-hour lab session should be able to:

1. Describe volume resuscitation methods using both peripheral and central venous access.

2. Interpret oximeters, ECG monitors, and vital signs, to follow the effects of resuscitation.

3. Describe invasive and non-invasive airway management techniques. Describe how teamwork can make this process succeed or fail.

4. State treatment modalities in herniation syndrome, and acute epidural hematoma scenarios.

5. Prepare and describe chest tube placement and management of chest suction devices including autotransfusion.

6. Perform and describe invasive emergency airway management and venous access in infancy.

Required Attire
Scrub tops and bottoms, shoe covers, and gloves. Surgical masks, protective eyewear, caps, and gowns are optional.

Although Q fever is carried by sheep (Rickettsia burnetti), it can be avoided with good hand washing technique, avoidance of mucosal contact, and inhalation of particulate matter. Q fever is an atypical pneumonia illness in humans treated with tetracycline. The sheep used in the laboratory come from Q fever free flocks. Also, pregnant and lactating sheep are the most common carriers, and are not used in this laboratory. Ecthyma contagiosum (orf) infection of sheep is manifested by herpes-like sores on the lips. It is caused by a sheep pox virus. It can be transmitted to humans by direct contact and results in a pustular lesion on the skin. It is self-limited and does not require treatment. Gloves and good hand washing technique are preventative measures.

Scrapie of sheep is related to bovine spongiform encephalopathy (mad cow disease), which is very rare in the U.S. It occurs in sheep older than those used in this lab. There are no reports of the prion material of bovine scrapie causing illness in humans.

Preparation of the Team

A brief explanation of the cardiopulmonary physiology of sheep (anemia, small RBCs, low blood viscosity, shifted oxyhemoglobin dissociation curve); fragility of the airway; comparable in size to a 7 year old child (24 kgs) and need for constant vigilance regarding vital signs is discussed. The "supine hypotensive syndrome" of pregnancy can be mimicked by the sheep's propensity for gastric distension with methane gas. Dependent pulmonary edema occurs in herbivores kept for prolonged periods on their backs. The animal is completely anesthetized as recommended by the institutional Animal Care and Use Committees. The animals are painlessly euthanized before regaining consciousness so as to avoid pain and discomfort. As in human medicine, especially as it is practiced in the emergency department, teamwork is essential. **An emphasis on teamwork is a hallmark of this laboratory experience.**

Table of Contents

Getting Started

The session begins with observing vital signs. Pulse oximetry has the following uses and limitations:

1. Keeps you informed of how well the patient's arterial blood is saturated with oxygen. The oxyhemoglobin dissociation curve is very steep when saturation drops below about 90 percent. As the level of saturation approaches 90 percent, you should become concerned.
2. Is a convenient method of monitoring pulse rate. It is not subject to artifacts, as are ECG monitors, especially during external or transvenous pacing.
3. Only tells you that the blood is oxygenated and not whether the patient is breathing well enough to exhale carbon dioxide adequately. A patient can be well saturated with oxygen and yet be in severe respiratory distress.
4. When cardiac output is very low or the patient is severely vasoconstricted, the arterial pulse is not detected in the digits.
5. Carbon monoxide saturation of hemoglobin is read as oxygen saturation by the monitor, giving a false high estimation of oxygen saturation.
6. Because sheep are normally anemic relative to humans, the curve is shifted to the right, resulting in a precipitous fall in saturation during intubation. The team's tempo of performance must be set accordingly.

Oxygen Saturation

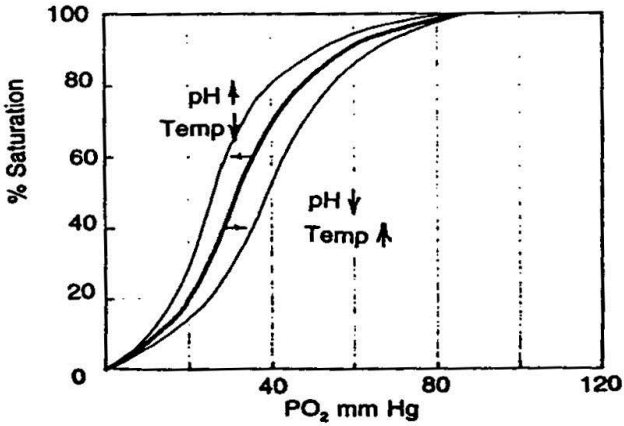

1. Distended Bladder in a Head Injured Patient Scenario

A male driver (not wearing a seatbelt) of a car involved in a rollover accident sustains a head injury and an unstable pelvic fracture. Blood is found at the urinary meatus and the bladder is clinically distended. Bladder decompression is needed to protect the brain from the increased intracranial pressure that occurs with bladder distension. IV mannitol may be needed and will quickly produce additional bladder distension.

Identification/Insertion of a Suprapubic Cystostomy Tube

1. Locate the bladder by palpation or ultrasound to determine if it is distended.
2. Prep the skin just above the pubis and insert the exploring needle of a percutaneous cavity drainage set (Arrow International, Inc. ®, kit AK Reading, PA) into the bladder. Aspirate about 2 mL of urine and re-inject it while watching the ultrasound. Turbulence in the bladder will be seen confirming correct placement.

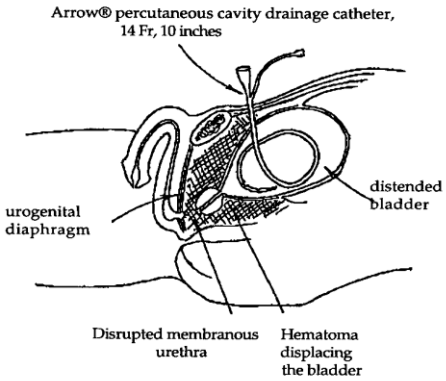

The coiled shape of the catheter keeps it in the bladder when it empties.

3. Insert the guidewire into the bladder, and before removing the needle, make a stab wound through the fascia into the bladder with a #11 scalpel blade held against the needle. Pass the 14 French dilator over the guidewire into the bladder. Remove the dilator leaving the guidewire in place.
4. Pass the 14 French curved drainage catheter over the guidewire into the bladder. Insert it all the way to its hub. Connect the catheter to bladder drainage system. Suture the catheter to the skin.

Splinting of Pelvic Fractures

Pelvic stabilization is a vital aspect of caring for a trauma patient with moderate to severe pelvic fractures. Every time a patient with this type of injury is moved or transferred there is a risk of causing hemorrhage from the involved internal iliac vessels as well as from the pelvic boney structures. There are a variety of methods that can be employed to stabilize the pelvis.
These include:

1. **Sheet and Towel Clips**
   Fold the sheet lengthwise, so that it is approximately 8 inches wide. The sheet should be passed under the patient (it is better to use a lift method rather than log rolling a patient with a moderate to severe pelvic fracture) and be placed no higher than the iliac crest. The sheet should have equal lengths on each side. The sheet is then tightened by pulling the ends in opposite directions and using towel clips to secure it (it may need to be pulled more than once).

2. **Sam Splint™ and T-Pod™**
   These are commercially made devices that can be used in place of a sheet. These devices basically act as a pelvic corset. Other, similar commercially made devices are also available.

3. **MAST (Military Anti-shock Trousers™)**
   The MAST can also be used, although, may not be as beneficial. They are especially useful for splinting pelvic fractures with concomitant femur fractures. Some studies have noted a deleterious effect in patients with head injuries and/or chest trauma.

Trauma Series X-rays

Prior to the arrival of the trauma patient, arrange three trauma blocks on the resuscitation cart. This will allow the patient's backboard to be off of the cart, facilitating insertion and removal of x-ray cassettes without having to lift the patient. The 4-inch blocks should be placed at head, mid abdomen, and knee levels, to facilitate obtaining c-spine, supine chest and AP pelvis views.

Algorithm for the Management of Pelvic Ring Fractures

Inspection of the perineum

Perineal laceration?

- Do not explore
- If bleeding heavily, pack with sterile gauze
- Diverting colostomy, I&D will be needed
- Start IV antibiotics

Testicular injury?

- Operative decompression later

Palpate for femoral pulses

Pulses decreased or absent?

- Iliac artery disruption may be present
- Angiography & vascular surgery will be needed

Rectal exam

Sphincter tone decreased?

- Possible sacral fracture, spinal injury
- Check for cauda equine syndrome later

Prostate high riding and boggy?

- Urethral transaction maybe present

Prostate findings equivocal?

- Assume transaction of the urethra is present

Blood in the rectum?

- Rectal disruption present
- Diverting colostomy, distal colon washout, pre-sacral space drainage will be needed
- Consult trauma surgery
- Start IV antibiotics

Inspect the penis

Blood at the meatus or penile injury?

- Blood at the meatus is not an absolute contraindication for catheter placement, gentle attempt is acceptable

External and bimanual female genitalia exam

Vaginal blood or laceration found?

- Operative I&D will be needed
- Start IV antibiotics
- Equivocal findings require speculum exam later

Insert Urinary catheter

- Urinary catheter contraindicated or unable to pass?
- Insert a suprapubic catheter if the bladder is distended

Inspect the back

If the pelvis is unstable, carefully lift the patient to see and feel the back, instead of using the log roll method for visualization

Preparation for Transfer of the Patient (Reminders)

- Endotracheal intubation for GCS < 11 (confused, combative), or respiratory distress
- Secure the ET tube and check position with a chest x-ray
- Ensure adequate paralysis, sedation, and analgesia for transfer
- Orogastric or nasogastric tube (orogastric preferable in trauma)
- Chest tube for pneumothorax or hemothorax
- Continuous exhaled CO_2 monitoring of intubated patients during transfer if available
- IV lines – minimum of 2
    - Convert to large bore lines if hypovolemic shock is present
    - Warm fluids
- Keep the patient warm
- O negative or O positive blood (for males and non-childbearing age females) for shock
- Examine patient's backside
- X-rays of cervical spine, chest and pelvis (trauma series)
- Maintain spinal immobilization (even after negative x-rays)
- Foley catheter or suprapubic bladder drainage as indicated
- Splint fractures
- Seizure prophylaxis (phenytoin or fosphenytoin load) for patients who are pharmacologically paralyzed with a GCS of 8 or less or who have intracerebral blood on CT
- Antibiotics (broad spectrum)
- Tetanus prophylaxis
- Copies of x-rays, lab results, flow sheets (can be faxed)
- Verbal report should be given doctor-to-doctor and nurse-to-nurse

Transport should not be delayed to allow for obtaining diagnostic studies.

2. Titration of Blood Volume Scenario

An obese, insulin-dependent diabetic, 16 year old female patient presents in severe DKA. Volume resuscitation is needed, but a 20 ga IV is all that is available and the team is unable to establish any other access.

Convert a 20 Gauge IV to a Large Bore Introducer

Using a Rapid Infusion Catheter (RIC) ® exchange kit, place the 0.025 inch diameter guidewire through an existing IV catheter into the vein. The existing catheter must be at least a 20 gauge to allow for passage of the wire. Remove the IV catheter and enlarge the skin opening slightly with a #11 scalpel blade, keeping the blade in contact with the wire. Use local Lidocaine if patient is awake. Place a 7 or 8.5 Fr rapid infusion catheter (Arrow International, Reading, PA) over the wire into the vein. Remove the dilator and guidewire simultaneously. Beware of orders to "run it wide open" because of the ability to give an excessive volume in a short time.

When the IV is established, blood can be drawn before connecting it to the IV line. A quick and safe technique for keeping the blood tubes correctly identified is to use a blood labeling system. Make individual bags of blood tubes prelabeled with a typed number and lab slips labeled with the same number. A wristband with that number is then applied to the patient. A labeled urine container should also be added. This technique is especially important when multiple patients arrive at once. Predetermine standard lab orders for the trauma and medical patient including a urinalysis and a urine pregnancy test in all females of childbearing age should be included.

Save a drop of blood for use with a reagent strip to quickly measure blood glucose in all critical cases.

Fluid Administration

Fluid administration in the setting of shock needs to be directed at the underlying etiology. In this case, an obese teenager is presenting in severe DKA. Cases such as this may require 3-5 L of IV fluids to stabilize the fluid imbalance. However, patients with underlying cardiovascular disease, sepsis, pregnancy, as well as other conditions, may be more challenging to manage. Therapy in these cases should be directed by closely monitoring the CVP to avoid volume overload (see measuring CVP below) while providing adequate fluid.

In the care of the trauma patients, the search for what is optimal fluid resuscitation is ongoing. Currently ATLS guidelines suggest an initial bolus of 1-2 L of warmed isotonic electrolyte solution (Ringers or NS) for adults and 20mL/kg in children should be administered. Subsequent fluid resuscitation decisions should be based on the response to the initial bolus, as well as evidence of adequate end-organ oxygenation.

Central Venous Line in the External Jugular Vein

Central Venous Access

Indications:

1. A peripheral IV cannot be established rapidly and IV access is urgently needed.
2. Volume resuscitation is being conducted in a patient at risk for overload. Eclampsia patients, traumatized pregnant patients, elderly patients, severely burned patients with a pulmonary injury are examples.
3. Central access needed for transvenous pacing.

Potential Complications

Pneumothorax, arterial puncture, the cannula goes up the internal jugular vein instead of the superior vena cava; the cannula goes into the pleural space and fluid is infused, air embolism, dysrhythmias.

Measuring Central Venous Pressure (CVP)

Measure central venous pressure using a saline manometer. A CVP of about 8-12 cm of H_2O indicates an adequate preload in most patients

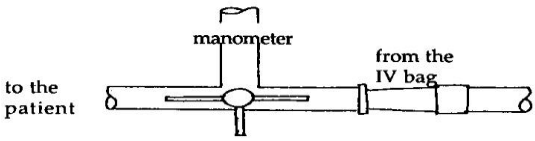

1. Flush the IV tubing to the patient

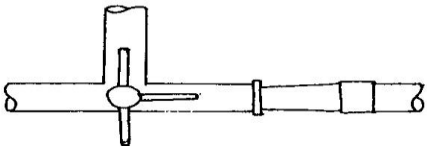

2. Fill the saline manometer from the IV bag

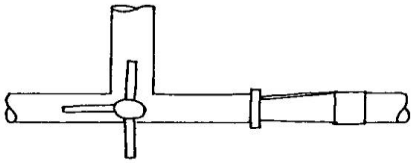

3. Open the saline manometer to the patient. The saline level will drop to the patient's central venous pressure and move up and down with respirations

Normal CVP is 4 to 12 cm of H_2O. **To convert readings to mmHg, multiply the pressure in cm of water by 0.7.** For example, a reading of 10 cm H_2O is equal to 7.0 mmHg.(monitor vs manometer reading).

Choice of Approach

In severe hypovolemia, even the central veins can collapse. Placing the patient in the Trendelenburg position helps by filling these veins and also by reducing the risk of air embolism. A substernal thyroid gland can distort anatomy significantly. No approach works all of the time, so physicians should be able to use any of these. A good rule of thumb is to give your first choice three tries, then move on to another approach.

Equipment

1. Two-lumen, Seldinger-technique, CVP lines or 8.5 French sheath introducer (18 ga/14 ga 7 Fr two lumen, or Arrow Trauma Kit®, Arrow International, Reading, PA).
2. Central venous pressure manometer.
3. Standard IV tubing to attach to IV fluid and then to the manometer.
4. When using multiple lumen catheters, one-way valves should be used; then there is no need to close the slide clamps.
5. Use ultrasound guidance when available.

Technical Points

1. Do not apply constant suction on the needle as you search for the vein, you will plug the needle with fat.
2. Listen for irregular beats on the ECG monitor when the guidewire is advanced. If premature ventricular contractions (PVCs) occur, pull back the guidewire. Set the monitor volume so the whole team will easily hear if this occurs.
3. The guidewire must always be held or kept in view to prevent inadvertent loss in the circulation.
4. If you hit the subclavian or carotid artery with your exploring needle, simply withdraw; the artery will heal itself. If, however, you insert an introducer and then discover it is intra-arterial, leave it in place. Consult surgery; an operating room will have to be ready when the device is pulled and an attempt made to tamponade the site. Fatal hemorrhage can result if everything is not ready.
5. Be very aware of the danger of air embolism. Always place the patient in the Trendelenburg position. Suture the catheter in place and make sure that the IV connections are securely locked together. The treatment for air embolism is: roll the patient to the left side with the head down so the air stays in the right side of the heart; listen for heart sounds and you may hear Hamman's "crunch"; aspirate blood and air

from the right heart; administer oxygen. If cerebral signs are present, hyperbaric oxygen treatment is indicated. Myocardial ischemia can also occur. Air embolism gets worse in decreased atmospheric pressure, so air transport can be problematic.

6. In infants and small children, 30 degrees of Trendelenburg is recommended to fill the central veins. The anatomic landmarks and needle directions are the same as with adults.

Infraclavicular Subclavian Approach

Always maintain the needle parallel with the floor. It is easier to keep the needle parallel with the floor if the skin is punctured several centimeters inferolateral to the point where the needle will go under the clavicle. The needle should go under the clavicle at the junction of its middle and medial thirds. If it runs into the clavicle, push the whole needle posteriorly rather than trying to angle the needle under the clavicle; doing so causes pneumothorax. If the needle goes into position but no blood returns, try the next stick with the needle directed more towards the larynx than the suprasternal notch. Pulling down on the arm may bring the subclavian vein closer to your needle. Avoid redirecting the needle while in the patient's body.

If you aspirate air, the lung has been penetrated and a pneumothorax is now present. If the patient will not be under drapes in the operating room and will not be put on a respirator, a small guidewire-assisted chest tube can be inserted. Otherwise, a standard chest tube will have to be inserted.

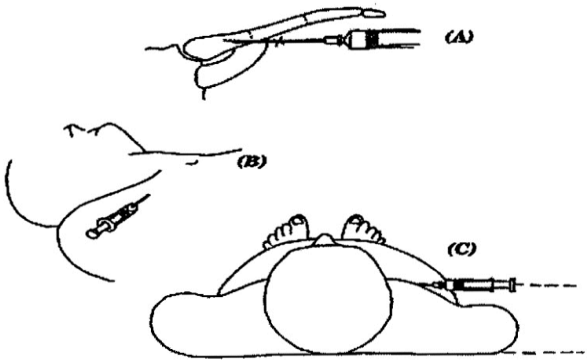

Three views of the infaclavicular approach:

(A) The needle enters the skin lateral to the junction of the medial and middle thirds of the clavicle then goes behind the clavicle at that junction.

(B) The needle is aimed at the suprasternal notch.

(C) The needle is kept parallel with the floor to prevent pneumothorax. The patient is in the Trendelenburg position.

Supraclavicular Subclavian Approach

The anterior scalene muscle separates the subclavian vein from the subclavian artery. This muscle forms the floor of the notch you feel at the lateral border of the SCM and the clavicle. The vein is encountered within 1-3 cm of puncture, or not at all, so do not go deep.

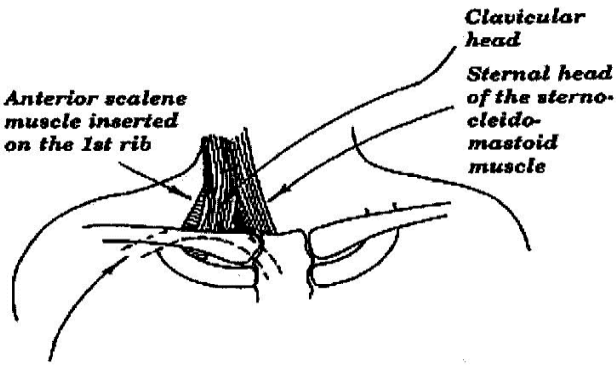

The subclavian vein lies between the SCM and anterior scalene muscle. The subclavian artery lies behind the anterior scalene muscle.

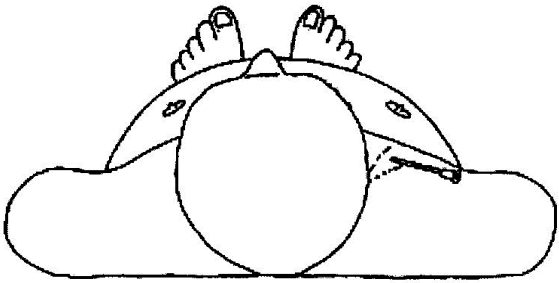

The patient is in Trendelenburg position. The exploring needle is directed towards the contralateral nipple in the notch formed by the muscles.

Internal Jugular Approaches

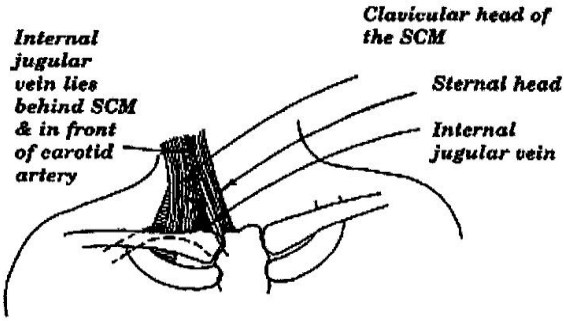

Anatomy of the subclavian vessels and the internal jugular vein in the neck.

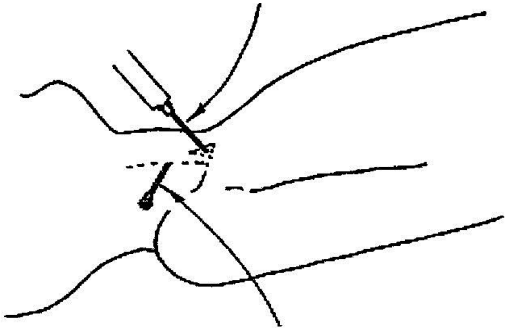

A. **Anterior approach to the internal jugular vein between the heads of the SCM.** The exploring needle with an attached syringe is directed posteriorly-inferiorly through the mid-portion of the SCM triangle. The vein is encountered within 1-3 cm of puncture, or not at all, so do not go deep. The needle should be directed inferiorly.

B. **Posterior approach to the internal jugular vein behind the muscle belly of the SCM.** With the patient in Trendelenburg, the exploring needle is directed under the SCM keeping it close to the muscle belly. The vein is encountered within 1-3 cm of puncture, or not at all, so do not go deep. When a patient's anatomy interferes with other approaches, this one still works. Keep the needle against the posterior aspect of the SCM to avoid the carotid artery.

Acidosis and Hypoxia
The patient with diabetic ketoacidosis is shocky and repeat blood gases either arterial or venous are helpful in guiding the treatment for severe metabolic acidosis and to determine the adequacy of fluid resuscitation. A radial arterial line would make access to arterial blood reliable and easy. An armboard with a block or curvature to hyper-extend the wrist for radial artery cannulation should be demonstrated.

Insertion of a Radial Arterial Line
Radial arterial lines can be inserted percutaneously or by cutdown. Prior to doing any radial artery stick, the Allen's test should be preformed to identify comprised circulation. If there is not a pulse palpable, a cutdown is necessary. The procedure is greatly facilitated by using an armboard with a block under the wrist and the hand held in extension with tape, or an armboard with a built-in wrist extension. Raise the cart so that the arm is at a comfortable working level. Swab the wrist with antiseptic solution. Preserve sterility by applying a stick-on 2.5-inch aperture drape.

1. **Percutaneous Approach**
   Wear sterile gloves. Use a guidewire assisted 6 inch 20 ga catheter (Argon Medical, Athens, TX). Palpate the radial pulse about one inch proximal to the flexor crease of the wrist.
   a. Insert the exploring needle and enter the artery while intermittently applying gentle suction with the syringe. When arterial blood is obtained, hold the needle very still. Do not try to advance the needle.
   b. Carefully remove the syringe and insert the guidewire into the artery. Little or no resistance should be felt. Remove the exploring needle and place the arterial cannula on the guidewire.
   c. Pull enough guidewire out of the artery to allow you to grasp the end of it at the hub of the cannula. Advance the cannula over guidewire into the artery. Remove the guidewire. Draw 1-2 mL of blood into a heparinized syringe and send it for blood gases.
   d. Securely suture the cannula in place. Attach it to the pressure tubing. The pressure transducer should be zeroed at the level of the heart. Flush the line and observe the pressure tracing for a good clean tracing.
   e. Apply a small dressing over the puncture site and hold it in place with clear film stick-on dressing.

2. **Cutdown Approach**
   Prepare the site as above. Using a #15 blade, make a vertical incision over the distal radius about one inch proximal to the flexor crease of the wrist. Carry this incision through the skin and into the subcutaneous tissues.

a. Insert a curved mosquito clamp into the wound and gently spread the blades as you work towards the distal radius. You may encounter veins, tendons and radial nerve branches. If you encounter tendon, you are too medial. Radial nerve branches are white and soft. The artery is substantive and elastic as opposed to veins that are thin walled and soft. The artery has a pink color to it. When you have found the artery, gently work your mosquito clamp under it and around it.
b. Using the mosquito clamp, pass a 000 silk suture around the artery. Do not tie it. Use this suture to apply distal traction.
c. Insert the exploring needle of the arterial line kit into the artery, and hold it very still while you insert the guidewire. Remove the needle.
d. Place the arterial cannula over the guidewire and pull out enough guidewire to extend out the hub of the cannula. Now pass the cannula over the guidewire into the artery using a suture for counter traction. Remove the guidewire and connect to the arterial line monitoring set-up.
e. Securely suture the cannula to the skin. Staple or suture the wound closed after removing the traction suture. Attach the line to the monitor and apply a dressing as previously described.

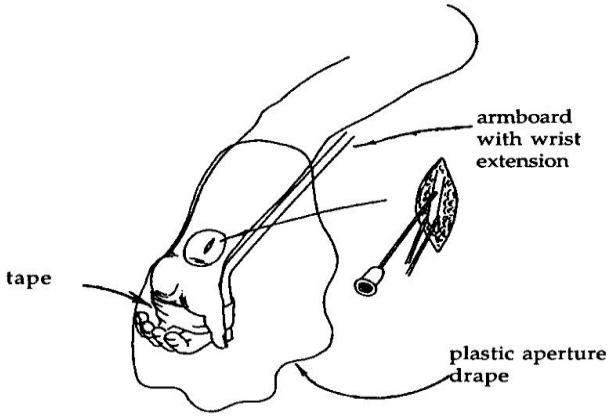

Radial artery cutdown.

Insert a femoral arterial line percutaneously using the same technique as described for percutaneous radial artery cannulation.

3. An Infant in Shock Scenario

A mother finds her 4 month old infant apneic and without a pulse in the early morning. Prehospital personnel are unable to establish an IV while resuscitation is attempted. A decision is made to insert an intraosseous needle.

The purpose of an intraosseous (IO) route is to obtain rapid circulatory access in order to provide necessary IV fluids, medications, or blood products. Any medication, fluids, or blood products that can be given intravenously can be given via the intraosseous route.

Insertion of a Manual Intraosseous Needle into the Proximal Tibia
Demonstrate the mechanics of inserting the needle into the bone:

1. Find the tibial tuberosity. Feel the flat surface of the tibia medial to it. Insert the IO needle through the skin and onto the flat surface of the tibia at a level just at the lower margin of the tuberosity.
2. Turn the needle guard down until it is ¼ inch from the skin. If there is a lock nut such as in the older version of the Sternal Illinois™ model, turn it down to the needle guard to lock it in place. In the Jamshidi™ model it is the lower phalange that controls the depth.
3. Place the hub of the needle in the palm of your hand and place your index finger on the shaft. Raise your elbow up so that your fingers, wrist and elbow form a straight line. Place your non-dominant hand behind the leg but not directly under the needle.
4. Rotate the needle back and forth against the bone. Be patient. You will feel a give when the needle enters the marrow cavity. Remove the hub of the needle and inject about 0.5 mL of saline then aspirate, a flashback confirms correct placement.
5. The needle may seem to be firmly implanted into the bone, but it can be easily dislodged, so someone needs to control it until a reliable IV is established elsewhere.
6. Use a T connector to attach syringes and stopcocks to avoid inadvertent dislodgement when fluid boluses and resuscitation meds are given.
7. Fluids may not flow through the IO needle with gravity or even an IV pump. A pressure bag or syringe bolus technique is usually needed. It can be secured with twill tape using a Lark's head hitch (see page 54).

Manual I0 Insertion in Adults
The Jamshidi Bone Marrow Needle™ 15 ga can be used in adults and 18 ga can be used in pediatrics. In adults, the IO can be used in the tibia just below the tibial tuberosity as note above, the distal femur, the humeral head and the manubrium. When using the manubrium, it is critically important to follow the one-quarter-inch rule as the aorta runs underneath. A typical scenario might be a cardiac arrested adult with no IV access. The manual IOs are being replaced in many hospitals by other devices such as the one shown below.

Correct body mechanics will ensure safe placement

EZ IO Insertion
The EZ-IO® Product System by Vidacare® consists of a small battery-powered device and two beveled, hollow drill-tipped needles that were specifically designed to provide safe, controlled vascular access via the IO route to patients of all ages. There are two separate needles with weight ranges of 3-39 kg and 40 kg or greater. The greater than 40 kg needle was designed with a beveled drill tip to penetrate through the hard exterior of adult bones, while the 3-39 kg needle is shorter in length for accessing the softer bones of pediatric patients. The tibia and the humerus can be used. For the tibia, the anatomical landmarks are the same as that used for pediatric IO access: just medial to the tibial tuberosity, on the flat portion of the proximal tibia. For the humerus, it is the anterior humeral head. Local anesthesia and prophylactic antibiotic administration are to be considered only if time permits. This needle can safely remain in place for up to 24 hours.

EZ IO

Contraindications to use of the EZ IO (or any IO)

1. Inability to locate landmarks.
2. Fracture or recent surgery of the extremity to be used.
3. Infection over the insertion site.
4. Severe osteoporosis, tumor of the leg, or knee replacement.

Procedure for insertion of EZ IO

1. Locate anatomical site and prep the skin.
2. Infiltrate the site with local anesthetic down to the level of the periosteum if needed.
3. Load needle into the driver; it attaches by a magnet.
4. Firmly stabilize the leg or shoulder near (not under) the insertion site.
5. Firmly press the needle against the site at a 90° angle and operate the driver. Use firm, gentle pressure
6. As the needle reaches the bone, stop and be sure that the 5 mm marking on the needle is visible; if it is, continue to operate the driver
7. Power the needle into the bone until the flange touches the skin or a sudden lack of resistance is felt.
8. While supporting the needle set with one hand, pull straight back on the driver to detach it from the needle set.
9. Grasping the hub firmly with one hand, rotate the stylet counter clockwise until loose, pull it from the hub, place it in the stylet cartridge, and place in biohazard container
10. The manufacturer recommends not attempting to aspirate bone marrow as it may clog the needle and tubing.
11. If the patient responds to pain (GCS $\geq$8), administer preservative-free Lidocaine, 30-50 mg for adults and 0.5 mg/kg for pediatrics IO slowly (30 sec.) (Do not exceed 3 mg/kg/24 hours)
12. If no signs of infiltration are found, attach the IV line and infuse fluids and medications as normal (IV bag will need to be under pressure)
13. Secure needle and dress the site.

EZ IO Insertion Sites

1. Proximal tibial – insertion site is one finger width medial to the tibial tuberosity.
2. Distal tibial -insertion site is two finger widths proximal to the medial malleolus and positioned midline on the medial shaft.
3. Proximal humerus - insertion site (see below)

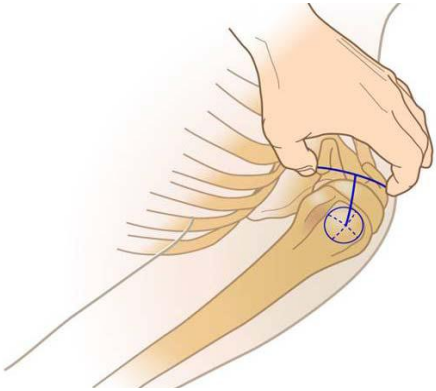

EZ IO Removal

1. Remove the attached EZ-connect extension set.
2. Attach a sterile 5 or 10 mL syringe luer lock syringe (the syringe will act as a handle).
3. Rotate the syringe clockwise.
4. While continuing to rotate the syringe begin gently pulling the catheter out avoiding the use of excessive force.
5. Apply a small sterile dressing to the site.

4. Elderly Patient with a Slow Heart Rate Scenario

An elderly male is brought in after fainting at home. He is awake, but his pulse rate is only 30 beats per minute. An attempt at external pacing fails, probably because he has emphysema and a barrel chest.

Transvenous Pacing

Use the Sensing Method
Use the Arrow Catheter Kit™, (Arrow International, Reading, PA). The kit contains a Touhy-Borst adapter, Arrow CathGard™, and 5 Fr balloon pacing catheter. Not all cases of heart block with shock respond to external pacing. Transvenous pacing is indicated when this occurs. A pacer lead can penetrate the right ventricle, so the possibility of cardiac tamponade should be considered.

Prepare
Assure that the ECG leads are attached. Try the sensing method first. Place an external defibrillator nearby. An O_2 saturation monitor is very useful for detecting capture.

Obtain Central Access
Perform central venous cannulation as described earlier. Wear a mask while performing this procedure. Insert the 6 Fr side port introducer contained in the kit. The right internal jugular and left subclavian is preferred for better success in passing the pacing wire into the heart. The Touhy-Borst adaptor on the 6 Fr introducer has a valve that can be tightened down, eliminating blood loss and restricting movement of the pacing lead. Lay sterile towels down over the field.

Insert the Pacing Lead
Place the 5 Fr bipolar pacing wire on the chest. The distal metal lead on this wire is the negative pole and the more proximal metal lead is the positive pole. Obtain the CathGard™ protector and put the pacing lead through it. This consists of an accordion length of soft plastic tubing that stretches out to cover the wire. Position the wire so that its natural curvature points the tip to the left (towards the heart). Start the wire through the Touhy-Borst valve. Hand the proximal end of the wire to another team member who will insert it into the appropriate lead hole on the pacing box. Turn the mA knob as low as it goes. Turn the pacing rate knob as low as it goes. Turn the sensing knob to the least sensitive (demand). Turn ON the pacing box.

Advance the Wire to the Ventricle
Advance the pacing wire down the superior vena cava while watching for the sensing light on the box to flash when the patient's native beat is sensed. When every native beat is sensed, the wire is in a position to pace the heart. It may be in the right atrium, floating in the right ventricle, or lodged against the right ventricular wall. Turn down the sensitivity of the box by turning the async-demand knob counterclockwise until sensing is lost. Now advance or retract the wire to regain sensing. This improves the wire's position.

Obtain Capture
Turn the rate knob of the pacemaker to the desired rate and the mA knob to 4 mA. The pulse rate sensed by the O_2 saturation monitor should equal the pacing rate. On the ECG, the pacer spike should be evident, followed immediately by a QRS complex. Now turn down the amperage until capture is lost (usually less than 1.0 mA). Turn up the amperage again until capture is regained. This is the threshold. Double it for safety and leave it at that setting. If the pacing wire is in the atrium and the patient has a third degree heart block, the pulse rate would not improve. The pacing spike will be seen to precede the P wave. Advance the pacing wire into the ventricle. If capture does not result, start over again.

Secure
Tighten down the Touhy-Borst adaptor to limit any motion of the wire. Extend the CathGard™ and carefully coil the pacing wire on the patient's chest and secure it with tape, always leaving the leads connected to the pacer box. Place the box in a plastic bag to assure that the knobs are not turned. Caution the patient about the importance of the wire and the pacer and why they must not be moved.

(Single chamber temporary transvenous pacing module Medtronic Model 5388 ™, Medtronic, Fridley, MN).

If the sensing method fails, use a continuous ECG monitor trace to aid in placement.

ECG Monitoring Method

Connect to the ECG V Lead

Connect the V lead of the ECG to the negative lead of the pacing wire. Set the ECG monitor to read the V lead.

Detect Intraventricular Placement

As the pacing wire advances down the superior vena cava, it will enter the right atrium. When it enters the right atrium the P-wave will become very prominent. It might have either a positive or negative deflection. When the pacing wire enters the right ventricle, a large QRS deflection will be seen. If the wire touches the myocardium, a large ST elevation will be seen, signifying an injury current. It will be possible to pace the heart even if the wire is not actually touching the myocardium.

Pace

Connect the leads to the pacer box. Set the knobs to 4 mA and demand. Set the rate knob to the desired rate. Turn it on. Capture should be obtained. Determine the threshold as above and double it for safety. The threshold will usually be less than 1 mA, but may be higher with myocardial ischemia.

A balloon catheter can be used. Test the balloon before insertion with air using the volume recommended by the manufacturer. Deflate the balloon prior to insertion. When the catheter is in the atrium, inflate the balloon so that the catheter is swept into the ventricle with the flow of blood. Deflate the balloon when ventricular placement is achieved. If the catheter is to be repositioned, do not pull back on the catheter with the balloon inflated.

5. Unconscious Teenager from a MVC Scenario

A teenager is involved in an MVC involving other victims. He is unconscious but has a pulse. He has a hard collar in place. There is alcohol on his breath. He is breathing inadequately. The EMTs are using bag/valve/mask ventilation with poor chest rise. There is a delay because of extrication problems, so there is time for the team to prepare and practice. Because of the inability to bag the patient, the team decides to proceed directly to orotracheal intubation, as there is no teeth clenching, rather than using rapid sequence intubation (RSI).

Team Assignments

1. A team member at the left side is responsible for assisting with laryngeal manipulation. The assistant should be familiar with three basic techniques: Sellick's maneuver/cricoid cartilage pressure, BURP maneuver, and external laryngeal manipulation.

   Sellick's maneuver/cricoid cartilage pressure is performed by utilizing the thumb and middle finger to stabilize the trachea while the index finger is used to press the cricoid cartilage posteriorly with a force of approximately 7-9 pounds (~35-40 newtons). The optimal pressure for this maneuver is still debated in the literature.

   The BURP maneuver is application of pressure to the thyroid cartilage by applying **B**ackward, **U**pward, **R**ightward **P**ressure. This manipulation is performed by the assistant again stabilizing the trachea with the thumb and middle finger while the index finger applies a backward force against the ***thyroid*** cartilage (~ 0.5 cm), followed by upward (cephalad) displacement until mild resistance is met (~ 2 cm), followed by rightward movement (~ 0.5-2 cm).

   External laryngeal manipulation (ELM) is performed by the intubator reaching around to the anterior neck with the right hand and manipulating the thyroid cartilage while attempting to visualize the glottic opening. Once the intubator identifies the optimal view, the application of pressure and tracheal manipulation is transferred to the assistant. This same technique can be performed also by having the intubator manipulate the trachea indirectly with the assistant holding the trachea and the intubator moving the assistant's hand.

   Caution needs to be exercised whenever a possible cervical spine injury is present. The assistant can also assist the intubator by gently moving the larynx side-to-side, helping him/her identify the glottic opening. The esophagus does not move. With any of these maneuvers, too much pressure may hinder an intubation, so there must be clear communication between the intubator and the assistant applying the

tracheal manipulation. Tracheal pressure should be maintained until the trachea is intubated, the cuff inflated, and the ET tube position is verified.

The team member also uses the bag/valve to ventilate the lamb. Lambs have lungs like a newborn baby. Attach a cm H_2O meter to the bag/valve system and note the pressure required to ventilate the lamb. Pressure should not exceed 30 cm H_2O due to an increased risk for barotraumas and pneumothorax. Mask seal cannot be achieved effectively in the lambs; so successful intubation must be accomplished.

2. A team member stands at the right side at chest level. This team member keeps the team informed of the O_2 sat readings and heart rate. When the lamb is intubated and the first breath is administered, this person listens over the stomach to pick up esophageal intubation immediately. Then both sides of the chest are auscultated. Each finding is spoken out loud for all the team members to hear.

3. A team member stands at the right side by the head. He/she hands the intubator all of the equipment he needs. He/she is also responsible for extubating the lamb, so several 10 mL syringes are at hand. When the ETT has been inserted, both the intubator and the person inflating the cuff should check the depth of placement – 23 cm for a tall person and 21 cm for a shorter person. Feel the pilot balloon of the ETT to initially gauge the amount of air injected. Once the tube position has been confirmed, the team member should re-assess the amount of air in the ETT cuff so that there is only a sufficient amount of air to prevent any air leak during respirations. Increased cuff pressure beyond that may lead to injury to the tracheal soft tissue. Once the ETT cuff is inflated appropriately, remove the syringe to avoid the accidental leaking of air from the ETT cuff.

4. The last team member is the intubator who stands at the head of the cart.

Equipment Needed

Suction Equipment

An oropharyngeal suction device with a large tip, an endotracheal suction catheter, and connecting tubing should be available. Also a commercially made suction bracket that fits under the cart cushion and keeps the suction tubing from falling on the floor, and also holds a tracheal suction catheter. The suction tip shown is a HI-D Big Stick™, which allows for better suctioning of large particles; there are also similar devices made by other companies.



Airway Cart

It is more convenient and efficient to arrange the airway tools on a moveable airway cart next to the intubator. The cart should have an adult side and a pediatric side. The tools should be laid out and ready to use. Place protective covering over the tools when they are not being used, but keep the tools visible so missing equipment can be easily identified. An airway cart prototype is shown below.

See Appendix 1 for a further description of the cart.

Laryngoscopes

Two laryngoscope handles are on each side. On the adult side, there are three sizes of Macintosh, Miller, and Wisconsin blades. No single blade will work well all of the time, so learn to use all three major varieties - Macintosh, Wisconsin, and Miller.

The curved Macintosh blade is inserted into the valecula, the space just above the epiglottis. Lift towards the opposite side of the room.

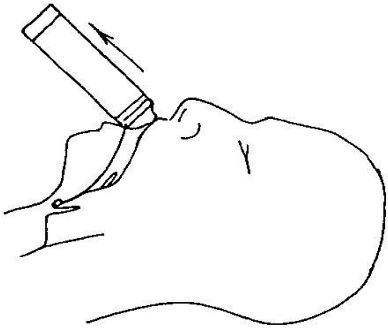

The straight blades are used to pick up the epiglottis, although the Miller blade can also be used like a Macintosh. The Miller blade has no flange to hold the tongue out of the way. This makes it easy to insert and is less likely to result in broken teeth. However, if the patient regurgitates or has copious secretions, the Wisconsin blade is easier to use because it has a large flange that holds the tongue well and gives maximum exposure of the glottis under these conditions.

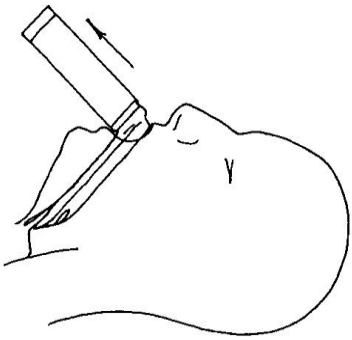

ET Tube Introducer (ETI)

The introducer, invented by Sir Robert Macintosh in the 1940s as the Gum Elastic Bougie, is a deceptively simple instrument. It is a 60 cm long, 15 Fr, firm but elastic disposable guide used to intubate the trachea. This is available through medical supply companies as is the Flex~Guide™ introducer.

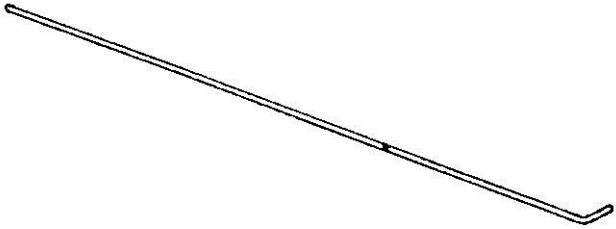

The Flex-Guide™ ET Tube Introducer

The adult ETI will fit through a 5.5 I.D. ET tube. A pediatric 10 Fr size will fit through a 4.0 ET tube.
The art of using this instrument correctly is as follows:
When the ETI is inserted the intubator can often feel the tip of its "hockey stick" end rattle over the tracheal rings, confirming correct placement. Even if this sensation is not felt, the ETI will meet resistance at the carina that will cause it to turn right or left. If it does not encounter such resistance, it is going down the esophagus. This turning movement is known as the Cheney effect. If the intubator preloads an ET tube on the introducer, he will lose this sensation.

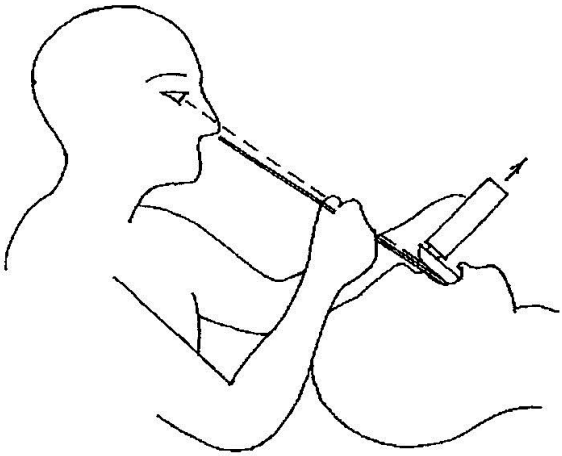

The intubator should stand or lean back so as to intubate at arm's length. This "limbo" position allows binocular vision and depth perception.

Hold the ETI gently between fingers without bending it. When the intubator can only see the arytenoids or the epiglottis, the ETI can be directed into the trachea by keeping the hockey stick end pointed forward. It is also useful when there is edema and cord spasm. The ETI should be inserted until the black ring is located at the corner of the patient's mouth. This indicates that there is enough length remaining to allow loading an ET tube with the ETI protruding from its proximal end. The black ring is 38 cm from the straight end of the ETI. Do not remove the ETI until the ET tube is in the trachea.

The line of vision through the blade is avoided by placing the ETI from the side

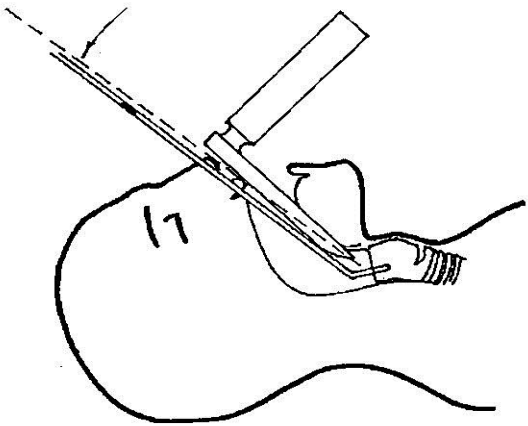

Another "trick of the trade" is to turn the ET tube 90° counterclockwise (to the left) as the tube nears the glottis. An effect called "railroading" is caused by the bevel of the tube getting caught on the arytenoid folds. This can be avoided by the counterclockwise turn. If it occurs, pull the ET tube back an inch to free the tip before turning it.



Esophageal Intubation Detector (EID)

The EID™ (Wolfe Tory Medical, Inc, Salt Lake City, Utah) is a device invented by Dr. MYK Wee, an Australian anesthesiologist in 1988, so it is often called a Wee tester. The device simply consists of a 60 cc syringe with an adaptor to fit the standard 15 mm connector of an endotracheal tube (there are several other versions available other than the Positube™ shown).

The Positube™ esophageal intubation detector

If the ET tube is in the esophagus and the syringe plunger is pulled back, the vacuum developed causes the walls of the esophagus to collapse around the end of the endotracheal tube, producing marked resistance to further movement of the plunger. Thus, there is no free flow of air. If the endotracheal tube is in the trachea, the plunger moves without resistance because the rigid walls of the trachea do not allow it to collapse enough to obstruct the end of the tube. Thus, there is free flow of air.

False results can be obtained under the following circumstances:

1. The patient has received positive pressure ventilation through an ET tube located in the esophagus. There may be enough air in the esophagus and the stomach to allow aspiration with little resistance. If this is a possibility, repeat the aspiration. This can also occur with prolonged use of a BVM, which allows air into the stomach.
2. The patient has severe pulmonary disease resulting in resistance to aspiration. Severe asthma and fulminant congestive heart failure are examples.
3. The patient is morbidly obese (400 lbs or so). The trachea can collapse secondary to the weight on the chest wall when suction is applied.
4. In children less than a year of age, the soft trachea can collapse.

Fortunately, these circumstances can be predicted clinically. The EID is accurate over 95% of the time. Other methods of confirming correct intubation are available. These include a CO_2 detector (Easy Cap™, Nelcor Puritan Bennett, Inc., Irvine, CA), which attaches directly to the ET tube. A color change indicates the presence of CO_2. Capnometry/capnography are monitors that show the presence of CO_2 either as a number or a waveform. CO_2 may not be easily detectable in cardiac arrested patients.

Emergency Orotracheal Intubation

Now that the team members are oriented to their roles, the patient arrives. Jaw lift technique and in-line immobilization are briefly discussed.

TRAUMA
Jaw Thrust maneuver

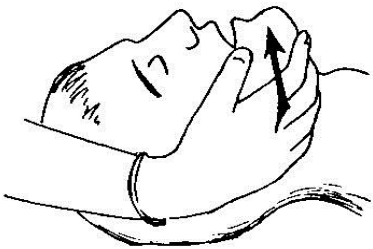

NO TRAUMA
Chin Lift maneuver

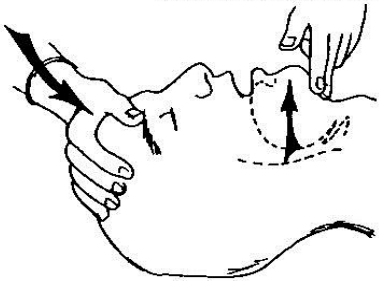

A team member kneeling at the head of the cart with their hands on the patient's shoulders with the head pressed between their wrists performs in-line immobilization. The patient is intubated while the team member stays out of the way. The hard collar is opened.

Lambs are more difficult to intubate than the typical human because there is almost always a severe degree of edema of the arytenoid folds. The vocal cords are rarely seen.

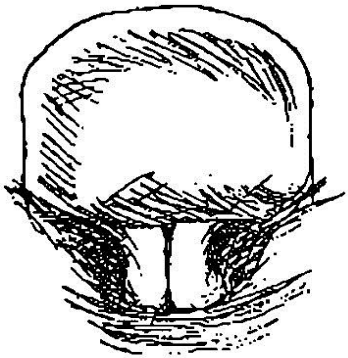

In lambs, the arytenoid folds are typically swollen shut making the ETI very useful



In humans, the vocal cords are usually easily seen

The lamb's propensity for laryngeal edema is advantageous for training purposes.

Each team member should intubate at least twice, once the standard way and once using the ETI.

Vomiting is simulated once without warning. In-line immobilization is maintained while the patient is log rolled to the right side. The intubator keeps the laryngoscope blade in the mouth while using the suction tip. This allows the intubator to use the laryngoscope blade to help visualize to clear vomit. After suctioning the patient is rolled back and intubation completed. Good teamwork should be used. Everyone should relay information immediately.

Replace a defective endotracheal tube using an ETI keeping the black line at the corner of the mouth. An ETI can be forced through a bronchus if this is not done.

6. Rapid Sequence Intubation Scenario

An inebriated woman has ingested a large amount of an unknown substance. She is very agitated and is struggling violently, threatening the emergency team members and preventing them from caring for her. She needs to be sedated and she is not adequately protecting her airway.

Ketamine 4-5 mg/kg can be given IM to allow for placement of an IV. Administer atropine (0.02 mg/kg IM) when using ketamine in children. Midazolam may be administered subsequently to avoid the bad dream effects of ketamine. The ketamine will take effect in 1-2 minutes.

Start a reliable IV and administer a paralyzing dose of **succinylcholine 1.5-2.0 mg/kg IV**. Err on the side of a large dose because partial paralysis can result in a non-breathing patient who is not sufficiently relaxed to allow intubation. Succinylcholine is kept refrigerated. It is drawn directly from its vial and is injected rapidly. Complete paralysis occurs in 50-60 seconds and lasts about 10 minutes.

When the succinylcholine takes effect in about 40 seconds, the patient is orotracheally intubated.

Rapid Sequence Intubation Basics

Succinylcholine will cause an elevation in serum potassium due to depolarization of the motor endplates of skeletal muscle. This rise may be dangerously exaggerated and cause dangerous hyperkalemia in patients who are a few days post significant burn or crush injuries or in patients with any type of chronic myopathy such as muscular dystrophy or in patients undergoing rhabdomyolysis. Care should also be exercised in patients who may have pre-existing hyperkalemia such as patients with chronic renal failure.

Succinylcholine is a muscle-depolarizing agent that causes transient muscle fasciculations. These fasciculations can cause a rise in intraorbital pressure. Avoid succinylcholine in the presence of a possible ruptured globe.

Succinylcholine also causes a transient rise in intracranial pressure. The transient rise in intracranial pressure with succinylcholine is less detrimental than the increased intracranial pressure associated with struggling and fighting against restraint thus it is used in head injury patients.

Patients with muscular dystrophy can develop malignant hyperthermia with succinylcholine. An uncommon hereditary cholinesterase deficiency can result in prolonged paralysis.

If laryngospasm ensues secondary to ketamine, the paralytic agent will reverse it.

Succinylcholine can cause bradycardia in children, so a child should receive atropine prior to intubation. As soon as the succinylcholine is administered apply posterior **pressure to the cricoid cartilage** to occlude the esophagus **(Sellick's maneuver)** as described previously. If the patient can tolerate it, another option would be to apply the Sellick's maneuver after the sedation is given. Usually the drugs are given simultaneously and this is not an issue.

The person administering the succinylcholine should announce its injection then count off ten second intervals until the patient is intubated. Wait about 40 seconds before attempting intubation. Lifting the patients jaw will indicate if paralysis is complete. Unfortunately, the masseter muscles are the last to relax.

The patient should not be bag/valve/mask ventilated during the interval between administration of the succinylcholine and intubation, unless it is necessary to prevent hypoxia, because it may result in stomach inflation. If positive pressure ventilation is necessary, cricoid pressure should be applied.

An alternative to succinylcholine **is vecuronium 0.1mg/kg**, a non-depolarizing agent. Vecuronium comes as a powder and has to be mixed prior to injection. The onset is in about 150 seconds and paralysis lasts about 30 minutes. It is this longer duration of action that makes it a second choice to succinylcholine in the usual case. It does not cause a rise in serum potassium.

A small dose of vecuronium can be used to prevent the muscle fasciculations of succinylcholine. The dose is 0.01 mg/kg or about 0.7 mg in a 70 kg person. This may prevent intraocular and intracranial pressure rise. This combination therapy can help overcome the disadvantages of using succinylcholine in a non-struggling patient with a head injury or eye injury when time is available.

When prolonged paralysis is needed, vecuronium can be used following RSI with succinylcholine. Also add midazolam 0.1 mg/kg for its amnesic and sedating properties because the anesthetic agent will wear off before the vecuronium.

Lidocaine 1 mg/kg IV can also be used to help prevent the intracranial pressure rise seen with the use of succinylcholine and in tracheal intubation.

Anesthesia is obtained with etomidate 0.3 mg/kg IV as soon as feasible, preferably before intubation because it will blunt the intracranial pressure rise seen with tracheal intubation, which occurs even in comatose patients. Etomidate is a good choice even in trauma patients as it does not cause or exacerbate hypotension. Etomidate takes effect very rapidly (30-60 seconds), so it can be administered immediately following or before the succinylcholine or vecuronium. Its effects last about 5 minutes.

Etomidate is not a barbiturate or narcotic agent. It is a carboxylated imidazole. It does not have analgesic properties, but its potent hypnotic effects produce a level of anesthesia that eliminates the need for analgesia. Once it affects wears off, the patient may need an analgesic. When used for rapid sequence intubation, it causes depressed cortisol levels for a brief period of time (3-5 hours) that does not pose a problem clinically. It can also cause cortisol suppression in septic shock. Prolonged use of etomidate may require the use of a steroid replacement.

Etomidate can produce localized myoclonic movement that can be difficult to distinguish from a seizure. It is short lived and does not require treatment. However, it can introduce a confusing element to some cases. This can be mitigated with the use of Fentanyl. Fentanyl 0.7-2 µg/kg IV anesthesia can be substituted for etomidate because it has few hemodynamic effects, also protects against intracranial pressure rise, and has an immediate onset of action. It lasts 30-60 minutes and can be reversed with naloxone. Midazolam 0.05 mg/kg IV should also be given with it because patients may remain aware of what is being said even though they appear anesthetized.

If the patient is suffering an asthma attack and needs intubation, substitute ketamine 2.0 mg/kg IV (with atropine 0.02 mg/kg with 0.1 mg as a minimum dose in children). Also give midazolam 0.05 mg/kg IV for its amnesic affects that protects against the hallucinatory “bad dream” effects of ketamine. Ketamine is recommended in asthma because it has a bronchodilating effect and because it does not release histamine.

Midazolam, if used alone as an anesthetic, is not reliably protective of intracranial pressure rise at its usual dosage.

Orotracheal intubation will not always be successful. The attempt at intubation should last up to 30 seconds. Oxygen saturation should not drop below 90. If so, go back to bag/valve/mask ventilation with continued cricoid pressure and try again after reoxygenation.

An ET tube introducer (ETI) is always useful, but especially if there is spasm of the cords, edema of the arytenoid folds of the laryngeal opening, or the laryngeal opening is only partially visible. It should be used when neck movement is to be avoided, as in a possible cervical spine injury.

If still unsuccessful in adults, resume bag/valve/mask ventilation until the patient begins breathing again. If the patient is apneic or is breathing inadequately and is of adult stature, use an LMA, King tube or an esophageal tracheal Combitube™ that can be inserted into the esophagus or trachea. It will work to oxygenate the patient until another attempt at orotracheal intubation or another route is chosen. In children, use a LMA or transtracheal needle ventilation if the patient cannot be adequately ventilated with a bag/valve/mask.

Rapid Sequence Intubation in summary - 9 Ps

1. **Prepare equipment -** laryngoscope, ET tubes, ET tube introducer, large bore suction, bag/valve/mask, rescue airway, prepare medications, establish an IV, apply monitors, and assign tasks to specific team members.

2. **Preoxygenate** - 100% O_2 by bag/valve/mask and oral or nasal airway for 3-5 minutes if possible.

3. **Premedicate** - children with atropine 0.02 mg/kg (0.1 mg minimum). When intracranial pressure is a concern; administer Lidocaine, 1 mg/kg IV. Consider the use of a defasiculating dose of vecuronium 0.01 mg/kg if time is available.

4. **Push sedative -** use etomidate 0.3 mg/kg IV that has an onset of action of 30-60 seconds and lasts 3-5 minutes. Alternatively, anesthetize patients in an **asthma attack** with ketamine 2.0 mg/kg IV with midazolam 0.05 mg/kg. Ketamine will take effect in 30 seconds and last about 45 minutes. It will act as a bronchodilator.

5. **Paralyze** - 1.5-2.0 mg/kg succinylcholine IV (err on the side of a large dose rather than an inadequate dose) that has an onset of action of about 50 seconds and lasts about 10 minutes. Do not bag the patient once the succinylcholine has been given to avoid gastric distension and regurgitation. The team member who administers the succinylcholine should announce the injection and count the elapsed seconds out loud at 5-10 second intervals until the patient is intubated.

6. **Pressure on the cricoid** - a team member should immediately apply cricoid pressure (Sellick's maneuver) to avoid regurgitation.

7. **Pass the tube -** at about 40 seconds orotracheally intubate the patient using in-line immobilization when trauma is suspected. If unsuccessful after about 30 seconds or when the oxygen saturation drops, resume using a bag/valve/mask to reoxygenate the patient then try again. An ETI can be very helpful. If still unsuccessful insert a LMA, King tube or Combitube™ in adult sized patients and use it for ventilation

according to whether it has entered the trachea or the esophagus. If a Combitube™ is used in the esophagus and the patient is awake, sedation and analgesia must continue. Alternatively, **LGI, ILMA, retrograde intubation** or **TTNV** could also be used.

8. **Patent airway assessment -** use an EID, end tidal CO_2 and check breath sounds.

9. **Post intubation plan -** if continued paralysis is needed, add vecuronium 0.1 mg/kg. Sedate with midazolam 0.05 mg/kg. Provide analgesia with fentanyl 2-10 µg/kg. Another option is to sedate with Propofol using initially 5mcg/kg/min until onset of peak effect. May increase by increments of 5-10 mcg/kg/min over 5-10 minute intervals. For maintenance use a drip at 5-50mcg/kg/min.

7. Difficult Airway Rescue Techniques Scenario

A middle-aged man with a history of hypertension who has just received fibrinbolytics for an MI develops a severe nosebleed. Blood is pouring from the nose and mouth. He becomes unconscious as his trachea fills with blood. An attempt is made to orotracheally intubate him using suction in attempt to clear the airway, but it is impossible to see anything.

Esophageal Tracheal Combitube™

The esophageal tracheal Combitube™ is a two-barreled tube that will function well when placed in either the trachea or the esophagus. Insertion does not require neck movement.

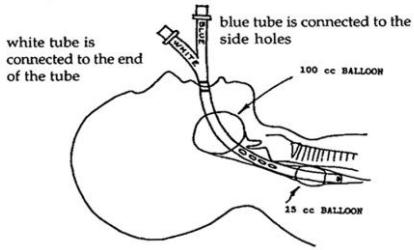

1. The tube is placed blindly with care to keep it midline. It is placed to a depth that lines up the teeth between the two proximal markings on the tube. Placing the tube too deeply will occlude the larynx.
2. The large 100 mL balloon is inflated in the posterior pharynx and the 15 mL distal balloon is then inflated. The balloons should be filled in the correct order, which is noted on each balloon and each tube.
3. The short clear tube is connected with the distal opening of the tube. Attach an esophageal intubation detector and test it for position. Do it twice if the patient has been bag/valve/mask ventilated. The blue tube is connected to the side holes.
4. If the tube is in the trachea, use it like an endotracheal tube. The large balloon will keep it in position.
5. If the tube is in the esophagus, ventilate the patient using the long blue colored tube. Listen for breath sounds over the chest to be sure the tube is functioning properly. Gurgling in the stomach occurs if the esophageal balloon is improperly inflated.

To replace the Combitube™ with a regular ET tube when it is located in

the trachea, pass an ETI through the white tube and remove the Combitube™. Pass a regular ET tube into the trachea over the ETI. The trachea can be intubated without removing the tube but it is very difficult. Deflate the large balloon and move the tube to the side of the mouth. Use a laryngoscope with a Macintosh blade to visualize the larynx and intubate with the aid of an ETI. Alternatively, pass a lubricated 14 Fr gastric tube through the clear tube to evacuate the esophagus and stomach. Deflate both balloons, remove the esophageal tracheal Combitube™ and intubate as usual.

The Combitube™ is almost an ideal rescue airway. The standard size will function well in almost any adult. A smaller size is available for persons between 4 and 5 feet tall. If the patient is conscious, it is very uncomfortable. It will not suffice in patients with laryngospasm or laryngeal edema. The latex balloon can be a problem in latex sensitive individuals.

If the Combitube™ is functioning well there is no need to replace it during resuscitation or for transfer. However, to avoid error bend the unused tube down and tape it there.

The Combitube™ is difficult to use in lambs because of the laryngeal edema. The hard palate of the lamb extends back to the larynx so the Combitube™ does not seal off the nasopharynx as it does in humans. A model of the larynx is used instead to help explain how it functions.

King Airway

The King Airway System™ (King LTS-D, King LT-D, King LT) is a supraglottic airway that is inserted blindly. There are both disposable tubes and tubes that can be autoclaved. It requires a smaller mouth opening (23 mm) and its S-shape design decreases the chance of the tube going into the trachea. There is a proximal pharyngeal cuff and a distal esophageal cuff; both are high-volume, low-pressure cuffs. It can be used on pedantic patients that are greater then 4 feet tall. It is contraindicated in patients with a gag reflex, caustic ingestion or airway burns, known esophageal disease (e.g. cancer, varices, stricture), height less then 4 feet and laryngectomy with a stoma.

Insertion

1. Apply chin lift and introduce the King tube into the corner of the mouth.
2. Advance tip under base of tongue, while rotating tube back to midline.
3. Without exerting excessive force, advance tube until base of connector is aligned with teeth or gums.
4. Inflate cuff according to package reference or volume noted on tube.
5. Attach resuscitator bag. While gently bagging, slowly withdraw tube until ventilation is easy and free flowing.

Awake Intubation

Awake intubation should be considered when the patient is breathing but needs to be intubated and has a condition or anatomic problem that may make rapid sequence intubation unsuccessful or dangerous. A blind approach, such as light-guided intubation, intubating laryngeal mask airway, nasotracheal or retrograde intubation could be used; combined with local anesthesia and analgesia.

1. Anesthetize the upper airway by ventilating the patient with Lidocaine administered through a nebulizer,
2. When coughing is to be avoided, 2 or 4 % Lidocaine can be injected directly through the cricothyroid membrane.

Laryngeal Mask Airway

The LMA™ airway is a supraglottic airway management device. The LMA™ system of products includes 6 airway devices and various accessories. Other companies have created similar devices. There is also the ILMA Fastrach™, which is designed to facilitate endotracheal intubation (described below).

The LMA Unique™ is relatively inexpensive and single use.

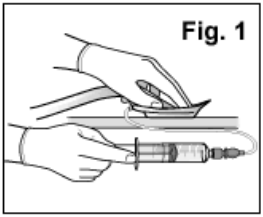

Tightly deflate the cuff so that it forms a smooth "spoon-shape" (Fig. 1). Lubricate the posterior surface of the mask with water-soluble lubricant.

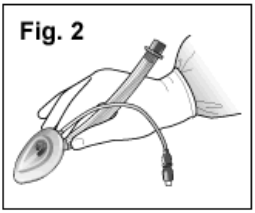

Hold the LMA™ airway like a pen, with the index finger placed at the junction of the cuff and the tube (Fig. 2).

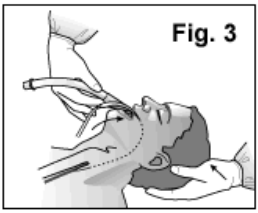

With the head extended and the neck flexed, carefully flatten the LMA™ airway tip against the hard palate (Fig. 3).

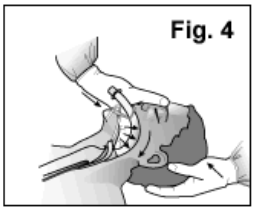

Use the index finger to push cranially, maintaining pressure on the tube with the finger. Note position of the wrist. Advance the mask until definite resistance is felt at the base of the hypopharynx (Fig. 4).

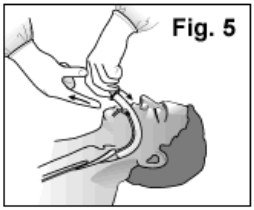

Gently maintain cranial pressure with the non-dominant hand while removing the index finger (Fig. 5).

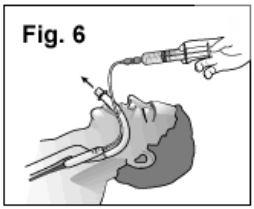

Without holding the tube, inflate the cuff with just enough air to obtain a seal (to a pressure of approximately 60 cm H_2O) (Fig. 6). Never over inflate the cuff.

Promotional illustration from LMA North America

Fastrach-Intubating Laryngeal Mask Airway (ILMA)™

The ILMA is another method of tracheal intubation that does not require visualization of the glottis. It is a reusable device. It is safe, effective, and relatively gentle. It does not require neck motion and can be used in an awake intubation.



Promotional illustration from LMA North America

How to use:

1. Select the appropriate size of ILMA - small adult size 3, normal and larger adult size 4, large adult size 5.
2. Place the ventral surface of the laryngeal mask on a flat surface. With a 20 mL syringe, aspirate the cuff so that it is flattened and tends to bend away from the ventral surface. Lubricate the posterior surface of the mask.
3. Hold the ILMA by the metal handle only. Open the patient's mouth and slide the mask in with its posterior surface on the hard palate. Continue this motion until the mask lodges in the introitus of the esophagus. In this position its ventral surface will be facing the glottic opening. Inflate the cuff with just enough air to provide a seal (15 to 40 mL).
4. Ventilate the patient with the ILMA. Slight adjustment in position may be necessary. Oxygenate the patient in this manner until ready to endotracheally intubate.
5. When ready to intubate, select either a standard polyvinyl chloride (PVC) ET tube or the straight silicone ET tube provided with the ILMA. Lubricate the tube. Insert the tube through the ILMA. If a PVC tube is used; insert it so that its normal curvature is reversed as it goes through the ILMA. This helps it round the bend into the trachea. Insert the tube to appropriate depth and inflate its cuff. Resume ventilations. Check for position as usual.
6. When ready to remove the ILMA, deflate its cuff. Remove the 15 mm adaptor from the ET tube. An obturator is provided with the ILMA. Use this to keep the ET tube at its correct depth while the ILMA is removed. As soon as it is possible, grasp the ET tube at the mouth (use of a Magills may be helpful) then remove the obturator. The ILMA can now be removed entirely. Reattach the 15 mm adaptor and resume ventilations.

If you are unable to intubate through the ILMA, it may be used to oxygenate the patient while retrograde intubation is accomplished.

Light Guided Intubation (LGI)

Light guided intubation or lighted stylet is a form of blind intubation that has a light that can be seen through the soft tissues of the neck especially when placed in the larynx or the trachea. There is disposable model called the Surch-Lite™ (available from Bovie Aaron Medical, St. Petersburg FL)**.** It can be used for awake intubation. It does not require neck motion and can be used with a hard collar in place. Morbid obesity (400 lb patient) is a relative contraindication to light-guided intubation.

Bovie Aaron Medical Surchlite™

To use:

1. Test the lighsourcet. The batteries can be replaced but these devices are disposable.
2. Select the appropriate endptracheal tube (can not be used with a tube smaller then a 5. 5 mm inner diameter).
3. Apply a water-based lubricant to the ETT opening to prevent the tube from sticking to the stylet as it advances.
4. Insert the lighted stylet into the ETT until the light source reaches the tip of the ETT tube and attach the ETT connector to the locking piece on the stylet.
5. Bend the ETT and lighted stylet to a 90 degree angle just proximal to the cuff

LGI is an easily learned skill.. LGI can be accomplished in the lamb model. Add 4 mL of 4 % Lidocaine and 2 mL of 0.25 % phenylephrine to the nebulizer. Assist the patient's respirations. Phenylephrine will dilate the pupils, so take care to avoid getting mist in the eyes. Even nasal drops can have this effect, so note the size of the pupils before and after administration. Phenylephrine shrinks mucous membranes and makes the Lidocaine more effective. A 10 % Lidocaine spray can also be used, but beware of overdosing a child. A single spray contains 10 mg of Lidocaine.

Video Laryngscopy
Video laryngoscopy is the cutting edge of technology. It is being used both in the prehospital and in the hospital setting. There are two that are more commonly used..

C-MAC® (Karl Storz) Video Laryngoscope is a new intubating device that is designed to provide a view of the glottis without aligning the oral, pharyngeal and tracheal axes. The CMAC may be especially useful in situations where intubation is potentially difficult. The C-MAC consists of a laryngoscope that attaches directly to a portable LCD screen via a single cable. The CMAC is shaped much like the other Macintosh blades that Storz makes. It has a thicker "pistol-grip" handle as opposed to the standard round laryngoscope handle but has the basic shaping of a standard Maintoshc blade. Laryngoscopy can be performed either directly without using the screen or indirectly by looking at the screen. This the basic difference between this device and the Glidescope; the ability to use the device with out using the screen

GlideScope® Video Laryngoscope (Verathon) is a system for laryngoscopy and tracheal intubation that utilizes a video camera embedded into a plastic laryngoscope blade. The blade is 18 mm wide at its maximum width (14 mm in newer models), and bends 60 degrees at the mid-line. This configuration was designed with the intent of providing a unobstructed view to that obtained with a conventional laryngoscope.

A light emitting diode (LED) solid state light source assembly is mounted beside the camera which provides illumination. The resulting monochrome video image is displayed on a (LCD) monitor, but can also be displayed externally or recorded electronically. It is cleaned using cold sterilization solution.

Nasotracheal Intubation

Nasotracheal intubation is especially useful in patients with fulminant pulmonary edema because it does not require laying them flat. It does cause coughing, so it may not be the first choice in most trauma patients.

1. Anesthetize the upper airway as described above. Select a 7 to 8 ID ET tube and lubricate it. Make sure the 15 mm adaptor fits tightly on the tube. Inspect the nares and insert a fingertip into each one to determine which one will accommodate the tube better.
2. Insert the tip of the tube into the selected nare and direct it directly posteriorly over the floor of the nasal cavity. As it rounds the bend at the posterior pharynx bleeding may occur. The Endotrol™ tube (Mallinkrodt Medical Inc., Irvine, CA) that has a controllable tip helps

avoid bleeding. It comes in sizes 7 and 8 ID. Bend the tip as it rounds the bend.

3. When the tube is at the glottic opening, you will hear the patient breathing through the ET tube. Protect yourself from exhaled material. Advance the tube into the trachea when the patient breathes in. This will usually stimulate coughing. When in doubt ask the patient to speak. If it is through the vocal cords, the patient will be unable to.

4. If it does not enter the trachea pull it back to where breathing sounds are heard and turn it 90º counterclockwise to avoid the "railroading" effect of the bevel getting caught on an arytenoid folds and try again. Another "trick" is to insert a tracheal suction catheter through the ET tube to stimulate coughing. When coughing is produced, advance the ET tube over the suction catheter. Alternatively, feel the tip of the tube in the neck and move the larynx towards that side as the tube is advanced. Yet another trick is to insert the lighted stylet of the LGI with its wire removed into the ET tube. The bright light can help determine where the tube is placed.

5. Insert the tube to about 28 cm in males and about 26 cm in females. Check for correct placement as usual.

Besides being a painful procedure, the main complication is bleeding caused by the ET tube scraping along the posterior pharyngeal wall or scraping the turbinates. Do not use this procedure in patients who have a bleeding diathesis, may receive fibrinolytics, may have a pharyngeal abscess or hematoma, or in whom bleeding will complicate the situation.

Retrograde Intubation

Retrograde Intubation is a good choice in patients who are breathing and have an anatomic problem that makes orotracheal intubation impossible or dangerous. It takes up to four minutes to accomplish, so it is not useful in an all-out emergency airway situation. The retrograde intubation set is made by Cook Critical Care™, Bloomington, IN.

Prepare for awake intubation as described above. Insert the exploring needle perpendicularly into the trachea just below the cricoid cartilage and aspirate for air confirming tracheal puncture. This needle has a stylet to avoid being plugged with cartilage. Angle the needle towards the mouth. Inject a few mL of 2% Lidocaine into the trachea to avoid coughing when the wire is inserted. Insert the long guidewire through the needle through the larynx while an assistant, using a laryngoscope, watches for the guidewire to appear.

The assistant uses a Magill forceps to grasp the guidewire before it goes behind the soft palate. If the wire goes behind the soft palate it may enter the cranium through a basilar skull fracture. The guidewire is pulled out of the mouth until a black ring on the guidewire reaches skin level. The needle is then removed and a clamp is placed on the wire at skin level to guard against inadvertent removal.

A long blunt obturator is then fitted over the guidewire and passed into the trachea. When it lodges against the junction of the guidewire with the trachea another black ring will be seen on the guidewire. Release the clamp on the guidewire and pull the guidewire the remainder of the way out through the obturator, taking care not to pull out the obturator. The obturator is advanced further down the trachea.

An ET tube is then passed over the obturator into the trachea. If the ET tube is caught at the arytenoids, it is pulled back an inch, turned 90º counter clockwise, and advanced. The obturator is then removed.

An advantage of using the retrograde technique is the ability to stop and ventilate the patient while the procedure is being conducted. It is also very useful when the anatomy is distorted by masses or hematomas.

Retrograde intubation

Transtracheal Needle Ventilation (TTNV)
TTNV can be performed on awake patients but the jet of oxygen in the trachea will stimulate coughing and it may require that the patient be paralyzed.

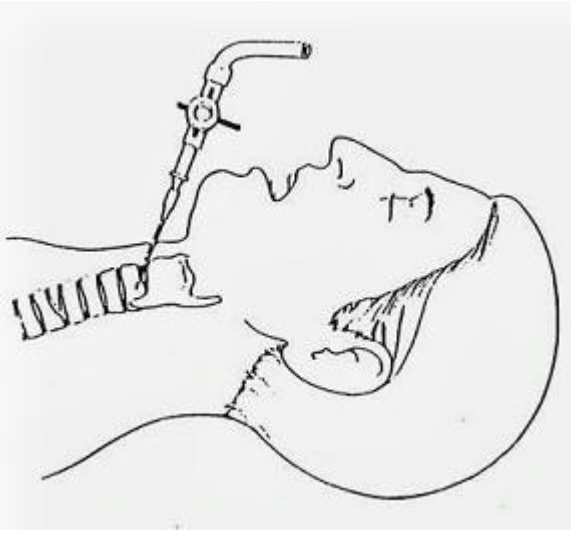

1. Palpate the neck identifying the tracheal rings, the cricoid cartilage, the larynx and the hyoid bone. The cricothyroid membrane occupies a small "fingernail" space between the cricoid cartilage and the larynx. When this is felt very easily, a skin incision is not needed. However, do not hesitate to make a generous incision if in doubt. The cricoid cartilage is hinged to the thyroid cartilage, so if the neck is extended the space becomes larger.

2. Attach a small syringe to a Cook™ Transtracheal Needle (8.0 French needle/cath, available from Cook Critical Care, Bloomington, IN - see figure 2) and insert the needle perpendicular to the skin in order to accurately penetrate the cricothyroid membrane. If the needle goes through cartilage, the remainder of the procedure will be very difficult. Intermittently aspirate for air. When air or mucous is aspirated; the needle is in the correct position. Do not advance it further. Gently angle it so that it points down the trachea. Now advance it down the trachea while casting off the catheter just as if starting an IV. Insert the catheter to its hub.

3. Aspirate with the syringe. You should get a free flow of air or

secretions. If not, pull back the catheter slightly and try aspiration again. When no resistance to aspiration results, you are ready to start ventilations.

4. The ventilating device, called the “moonlighter’s device,” is made by cutting off the tip of an 18 French tracheal suction catheter and attaching a male Luer connector (either metal or plastic will work) from blood pressure cuff tubing. It is connected to an oxygen flow meter (50 psi) with standard oxygen tubing. Ventilate by intermittently covering the suction port with your thumb. Set the flow meter for 15 L/minutes for adults and about 10 L/minutes for children. A newborn is well ventilated at 5 L/minutes. Watch for rise and fall of the chest as when using a bag/valve/mask. If **exhalation does not occur, do not continue.** There are also commercially made devices (see figure 2).

5. Do not let go of the catheter. Whoever is ventilating must hold the catheter at all times. Ventilate as if using a bag/valve/mask, watching the rise and fall of the chest. Leave time for exhalation to occur. Secretions are going to be blown out of the trachea and mouth, so protect yourself. Placing an oral airway in the mouth will aid in exhalation.

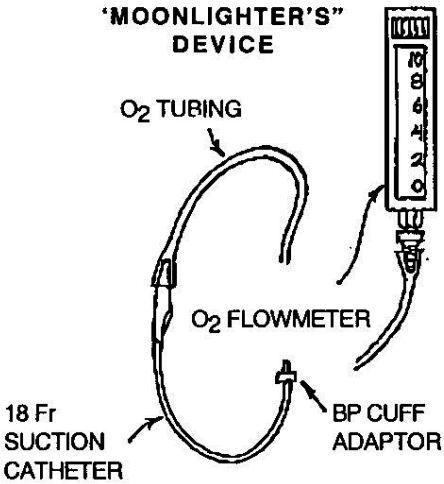

Figure 1

Cook ENK Oxygen Flow Modulator

Figure 2

Complications include barotrauma to the bronchioles and pneumothorax. Oxygen can dissect around the catheter in the neck and dissect down into the mediastinum. Sometimes a thin layer of pneumomediastinum can be seen on chest x-ray, this will clear spontaneously. It is a time-limited technique because it does not allow for efficient escape of carbon dioxide from the bloodstream and causes drying out of mucosa caused by the unhumidified oxygen. TTNV can be safely performed for at least 30 minutes and probably longer. Normal blood gases can be maintained. TTNV is a very useful temporizing method until a definitive airway can be established. It makes orotracheal intubation easy.

8. Motorcyclist Hits an 18 Wheeler Scenario

A motorcyclist runs into the back of a semi at high speed. He is a large man with no neck and a big beard. On arrival it is noted that he has severe facial trauma with blood coming out of his mouth and nares. He is in shock and is not breathing.

Cricothyrotomy

Various cricothyrotomy techniques have been described in the literature. The 'no-drop' technique, 'rapid four step' technique, and the cricothyrotome technique are the most often described. We will be performing the cricothyrotomy with a technique that makes use of the some of the same equipment and principles that we have already applied during our previous standard intubation cases.

Because the patient in this case is older than eight years, cricothyrotomy can be preformed. In younger children, the cricoid cartilage is fragile and forms a tight ring that can make insertion of a tube difficult. Children less than 8 years of age who need a surgical airway should have transtracheal needle ventilation followed by a tracheotomy.

1. If you are right handed, stand on the patient's left side. Palpate the neck identifying the tracheal rings, the cricoid cartilage, the larynx, and the hyoid bone. Grasp the trachea and larynx between the middle finger and the thumb of your left hand.

2. Make a 3-4 cm vertical incision over the proximal trachea and the larynx using a #10 scalpel. Carry this incision down to the strap muscles. The wound will gape open when you have incised through the subcutaneous tissues, indicating that the incision is deep enough. You do not have to visualize the strap muscles or the airway structures.

3. Insert the index finger of your left hand into the wound. You will be able to easily palpate the larynx and the cricoid cartilage. Insert a large tracheal hook (Ruiz hook available from Sklar Instruments, West Chester, PA) through the cricothyroid membrane that lies between the larynx and the cricoid cartilage to lift either the larynx or the cricoid cartilage and provide traction. This is easier to accomplish if the hook is placed from the side.

4. Hold the hook towards the chin if the anatomy is relatively normal, pulling the cricoid cartilage and trachea to a superficial position. You can have an assistant do this for you. Otherwise, if the anatomy is difficult as the chin and/or the beard is in the way, hold the hook towards the sternum, lifting up the cricoid cartilage.

The elevation of the thyroid or cricoid cartilage with the hook should be performed cautiously. Excessive lifting force may lead to significant injury and should be avoided. The assistant should hold the hook in position after placement, until confirmation of correct placement.

5. Position the #10 scalpel transversely and hold it against the hook. Hold the scalpel near the blade and incise the cricothyroid membrane. Holding the scalpel in this manner will reduce the risk for plunging the scalpel too deeply and perforating the posterior wall of the trachea and beyond. You will feel a distinct give when the trachea is entered. Hold the scalpel in place and dilate the opening with a mosquito or twist the scalpel until the opening is adequate. Because you have placed the hook and you are applying traction, the trachea should not move.



A midline incision results in less bleeding than a transverse incision. It can also be extended if needed.

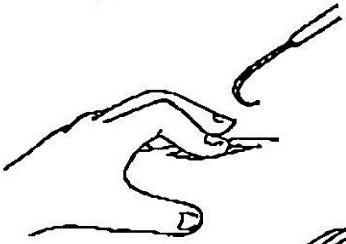

This technique is performed by feel. Even if there is bleeding, the membrane is easily felt.



In this example the hook is pulled up over the chin. If there is not enough room, pull it up over the sternum.



The knife is inserted next to the hook.

6. Insert a shortened and sterilized ETI and feel it move down the trachea over the tracheal rings. Shorten the ETI six inches from its straight end.
7. Place a 5.0-6.0 ET tube on the ETI and advance it into the trachea, inflate the cuff, and test its position with an esophageal intubation detector (EID). Ventilate. If all goes well, remove the hook.
8. Hold the ET tube until it is secured in place using a length of twill tape.

Cricothyrotomy is a rapid and safe method of securing an airway. It can be performed under the direst circumstances. It requires very few tools. The exception would be the patient with a laryngeal injury in whom a tracheotomy would be indicated.

9. A Snowmobiler with Neck Trauma Scenario

An adult male hits a wire fence with his neck while snowmobiling at a high speed. He has stridorous breathing when found. He arrives in shock and is barely responsive. There is a linear mark on his neck and the thyroid cartilage feels soft. A laryngeal injury is suspected.

In such a case, a single attempt at orotracheal intubation can be made. However, if the trachea has been separated from the larynx, the trachea can be pushed under the sternum by the ET tube. Do not push the ET tube against resistance.

Tracheotomy

Going directly to a **tracheotomy** would be a good choice. If the patient has a short, thick neck the trachea may be behind the sternum. The patient will not survive without an airway, so risking an exacerbation of a spine injury is of secondary importance. Place a rolled towel behind the shoulders to extend the neck enough to make the trachea palpable. The procedure is very similar to performing a cricothyrotomy.

1. If you are right handed, stand on the patient's left side. Palpate the neck identifying the tracheal rings, the cricoid cartilage, and the larynx.

2. Make a 3-4 cm vertical incision over the proximal trachea and cricoid cartilage. Carry this incision down to the strap muscles.

3. Insert the index finger of your left hand into the incision. You will be able to easily palpate the cricoid cartilage and the tracheal rings. Insert a large tracheal hook (made by Sklar Instruments, West Chester, PA) between two tracheal rings one or two rings below the cricoid cartilage. This is easier if you insert the hook from the side. In the rare instance in which the thyroid isthmus is in the way, push it caudad on the trachea using the handle of the scalpel or a gauze covered finger.

4. Hold the hook towards the chin if the anatomy is relatively normal, pulling up the cricoid cartilage and trachea to a superficial position. You can have an assistant do this for you. Otherwise, if the anatomy is difficult because the chin and/or beard are in the way; hold the hook towards the sternum, lifting up the trachea. An assistant can also do this.

5. Position the #10 scalpel transversely and hold the scalpel near the blade to prevent inadvertent plunging as discussed in the previous case. Now stab straight back into the trachea. You will feel a distinct give when the trachea is entered. Turn the scalpel 90°and repeat the stab so as to produce a cruciate incision into the trachea. Twist the scalpel to enlarge the hole, and then withdraw the scalpel. Because you have placed the hook

and you are applying traction, the trachea will not move.

6. Insert a shortened and sterilized ETI and feel it move down the trachea over the tracheal rings. Shorten the ETI six inches from the straight end.
7. Place a 5.0-6.0 ET tube on the ETI and advance it into the trachea, inflate the cuff, and test its position with an esophageal intubation detector (EID). Ventilate. If all goes well, remove the hook.
8. Hold the ET tube until it is secured in place using a length of twill tape.

How to Secure an ET Tube
There are many good ways to do this. Here is a relatively simple method.

Use a long piece of twill tape and form a loop at the middle of the tape. Pass the loop around the ET tube and pull the tape through it to form a Lark's Head hitch as shown below. Assure that the hitch will not slip by tying a single overhand knot around it as shown. Pass one limb of the tape around the patient's neck using a Magill forceps to pull it around without neck motion then tie the two ends together.

When securing a tube at the mouth or nares, pass the twill over the ears and then around the neck.



The Lark's Head hitch

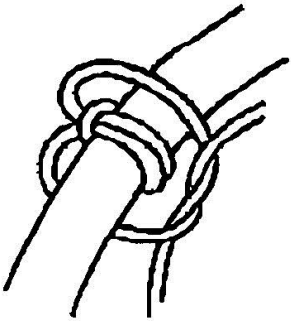

Add a simp1e overhand tie

10. An Aspirated Piece of Meat Scenario

A seventy-year-old man with false teeth aspirates a large piece of meat while wining and dining with his family. The Heimlich maneuver fails to expel the meat. He is able to breathe if allowed to lie still. He is rushed to the ED after 911 is called. After he arrives complete obstruction occurs before any preparations can be made. The Heimlich maneuver continues to be unsuccessful.

Foreign Body Extraction (Vacuum Method)

Tools Needed:
An ET tube introducer (ETI); a 60 ml syringe style esophageal intubation detector (EID); a laryngoscope; an ET tube; a Magill forceps; a meconium aspiration adaptor; and a scissors.

Procedure:

1. Two rescuers work together. Ventilations are attempted. If there is **partial obstruction**, do not proceed. Support oxygenation as best as possible and arrange for emergency endoscopic removal, if available. If the situation is life threatening or complete obstruction is present, proceed with this effort.
2. One rescuer starts chest compressions while the other prepares to intubate. Unless the foreign body can be grasped with a Magill forceps they quickly proceed with intubating the trachea with a modified ET tube.
3. The tip of a 7.5 ET tube is cut off squarely just proximal to the Murphy eye. The modified ET tube is advanced down the trachea with the aid of an ETI until slight resistance is felt. Cricoid pressure may ease this process.
4. If high volume, high negative pressure vacuum is available (as in a typical wall outlet vacuum), a meconium aspiration adaptor is attached to suction tubing with the vacuum set at maximum. The meconium aspiration adaptor is attached to the ET tube and vacuum applied to pull the obstructing object from the trachea.
5. If a vacuum source is not available, an EID is attached to the ET tube. The rescuer applies a vigorous pull on the plunger resulting in a vacuum seal between the ET tube and the meat. The plunger should not be pulled completely out of the syringe barrel. The rescuer then pulls out the ET tube while sensing the vacuum in the syringe. If vacuum is lost, the rescuer pushes the plunger back into the EID without removing it and advances the ET tube back down the trachea and repeats the process.

The second rescuer is ready with a laryngoscope and Magill forceps in case

the object is only partially pulled through the larynx.

Even if the foreign body is not extracted, reattempt ventilation because it may have been dislodged or pushed into the right mainstem bronchus.

In the laboratory, a large soft plastic fishing lure, available in bait shops, is used to simulate a piece of steak or a part of a vinyl glove is used to simulate a balloon. It is large enough to obstruct the trachea. A glass replica of an adult human trachea is used for teaching the process.

Vacuum Extraction of a Balloon from a Child's Trachea

As before, if only partial obstruction is present, temporize until formal bronchoscopic removal can be arranged. If, however, the child is in mortal danger, proceed as follows:

Tools Needed:
An ET tube appropriate for the child's age and size; an ET tube stylet; a Magill forceps; a meconium aspiration adaptor; and a scissors.

Procedure:

1. Cut off the tip of the ET tube parallel to the bevel but proximal to the Murphy eye;
2. Insert the ET tube stylet in the ET tube as is standard practice;
3. Apply lubricant;
4. Intubate; and
5. If high volume, high negative pressure vacuum is available, attach the meconium aspiration adaptor to suction tubing with the vacuum greater than 150 mmHg negative pressure.

This is the same as with meconium aspiration of the neonate except the ET tube is cut proximal to the Murphy eye and more than 100 mmHg of negative pressure is needed.

An EID can be used when a vacuum source is not available. The rescuer will not be able to sense the balloon on the ET tube, so it should be pulled out quickly while the plunger is being pulled out of the barrel of the syringe.

11. Blunt Chest Trauma Scenario

A farmer is injured when his tractor overturns in a field. An object struck him on the left chest. On examination his airway is okay but he is having difficulty breathing. His trachea is shifted to the right, his neck veins are distended, and his pulse is weak. There is crepitance on palpation of his left chest. He is obtunded. He is orotracheally intubated with in-line immobilization without difficulty.

Needle Thoracostomy for Tension Pneumothorax

Equipment: Cook ™ needle thoracostomy set, (Cook Critical Care, Bloomington, Indiana; ***with syringe attached.***

1. Palpate the 2nd intercostal apace at the midclavicular line on the affected side. This is between the 2nd and 3rd rib.
2. Prep the area.

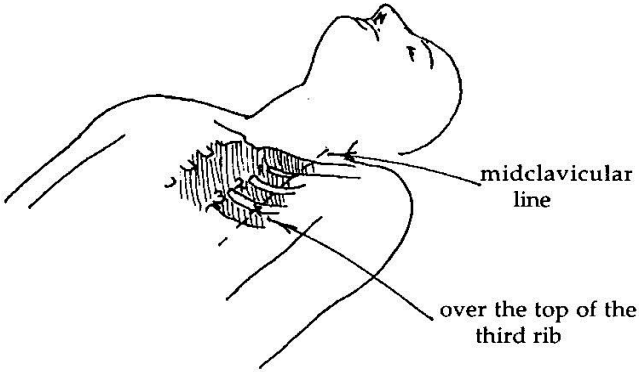

3. While holding the syringe, place the index finger at the point on the catheter/needle that you expect will be the depth required to enter the chest cavity. Insert the needle over the top of the 3rd rib, into the chest cavity, using your index finger to avoid going in too far. A distinct give will usually be noticed. Check for air, when air is aspirated, CAST off the catheter, keeping the needle and syringe stable. When the catheter has been placed to the hub, remove the needle. You *may* hear a rush of air.
4. Attach a flutter valve (Heimlich valve or similar) to the catheter with the connecting tubing.
5. Check vital signs and listen for breath sounds.
6. Apply positive pressure ventilation to re-expand the lung.
7. A chest tube should be inserted as soon as possible. Connect the chest tube to the suction apparatus.

Tension pneumothorax is the progressive build-up of air within the pleural space. This build-up of pressure obstructs venous return to the heart, leading to circulatory instability. It is a clinical diagnosis. It should be considered in any patient in shock. Observe for abnormal chest excursion, hyperresonance; distended neck veins, (though patients may not show this finding if they are hypovolemic); tracheal deviation to the side OPPOSITE the pneumothorax, loss of breath sounds on the affected side, rise in airway pressure, hypoxia. One or all of these findings may be absent. The patient may just be tachypneic, tachycardic. Tension may develop suddenly or insidiously. Tension pneumothorax is a cause of pulseless electrical activity (PEA).

Use needle thoracostomy in patients with evidence of TENSION pneumonthorax, it is NOT indicated in the case of a simple pneumothorax.

Chest Tube Insertion for Trauma

When a chest tube is critically important to the patient's care, follow this procedure to assure that it goes into proper position and is functioning.

1. Feel the 5th intercostal space at the sternum to identify the correct level at which to insert the chest tube. Identify the intersection between the anterior axillary line and a line drawn across the chest from the 5th intercostal space. This will be the site of insertion. Feel the underlying rib. Double glove, because glove damage is very common during chest tube insertion.
2. Use generous quantities of 1 % Lidocaine to infiltrate the area if the patient is awake. If the patient has broken ribs and is awake, the procedure will be very painful despite the Lidocaine, so administer etomidate 0.1 mg/kg IV. It takes effect in 30 seconds and is worn off in 3-5 minutes. Another choice would be to give Fentanyl and Versed in incremental doses.
3. Make a 3 cm long incision over and in line with the selected rib with a #10 scalpel. Carry this incision into the subcutaneous fat. Use a curved blunt forceps (Carmalt clamp) to tunnel over the selected rib. Force the clamp over the top of the rib and into the chest. If the patient is being ventilated, stop ventilating at this time so that the lung is deflated. If the patient has broken ribs this is very painful so you may want to spread the jaws of the clamp as you work through the intercostal space so less pressure is needed. Spread the interspace widely. Insert a finger into the chest to make sure that the lung is not adherent to the chest wall at that point. Use your little finger for this if the opening is tight. If the patient is very muscular, adequately opening the interspace can be difficult. Replace the Carmalt clamp with the jaws of a double curved renal pedicle clamp (Guyon-Paen) and spread so that you can see a path into the chest.

4. Select a 36 French chest tube and place it on the chest so that you will know when it has been inserted far enough. Arm it by placing the jaws of another Carmalt clamp through its distal side hole. Replace your finger in the chest with the chest tube and direct it cephalad and posterior attempting to reach the apex of the chest. If the chest tube comes with a trocar, insert the trocar now but not so far that it protrudes from the end. This stiffens the tube and aids in correct placement. Disconnect temporarily from positive pressure ventilation so that the lung collapses. Reconnect the ET tube as soon as the tube is in position. Suture the tube in place using a ‘0” silk suture or other large braided suture, tightly around the tube leaving two long limbs of suture to wrap around the tube. Finish closing the incision with skin staples.

5. If the chest tube fills with blood, quickly clamp it with the Carmalt clamp. Alert the team that a blood collector should be attached to the chest suction apparatus for possible autotransfusion unless the injury suggests that there may be abdominal injury with contamination of the chest cavity with bowel or gastric contents.

6. Apply a sterile dressing around the chest tube. Attach the chest tube to suction. It is very important that all connections of the tubing be secure. A convenient method is to use nylon cable ties available from your hardware store. These are tightened using a clamp or a banding gun. When disconnecting the chest suction apparatus from its vacuum source, in order to move the patient, do not clamp the chest tube. Tension pneumothorax can develop if the tube is clamped, especially if there is an air leak in the lung. When space is limited, as in a helicopter, a Heimlich flutter valve can be substituted for the chest suction.

7. If the patient is bleeding massively from the chest through the chest tube and the blood pressure falls precipitously, the blood in the chest may have had a beneficial tamponade effect. In that case, clamp the chest tube and observe for effect.

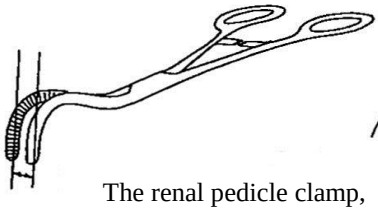

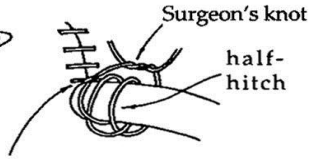

The renal pedicle clamp, also known as a kidney clamp, is useful because the curve of its blades hold the wound open

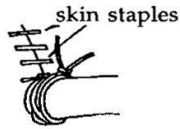

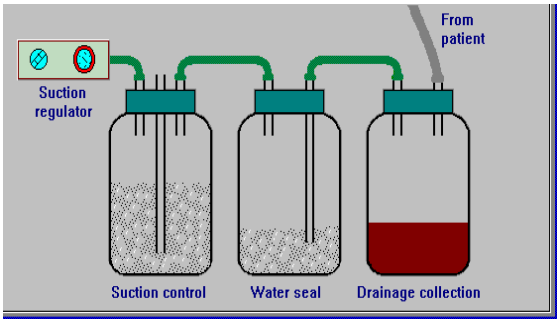

Almost all chest drainage systems employ three principles.

1. Collection chamber
2. Water seal chamber – water seal bubbles indicate an air leak
3. Suction chamber - the depth sets the vacuum pressure

A negative pressure of 20 cmH_2O is usually used. In many of the newer chest drainage systems this 20 cmH_2O pressure is a "dry suction" system that does not require the addition of water for suction. The newer chest drainage systems also now have an “air leak meter” rather than a water seal that needs to be filled to function but does need to be filled to check for an air leak. Make sure you know what type and how to set-up your own chest drainage systems as there are subtle differences between brands. An air leak can result from an abnormal communication between the bronchial tree and the pleural space or it can result from a leak in the system. Test for a system leak by clamping the chest tube. If the leak continues, one of the tubing connections is loose. If the leak stops, the leak is in the coming from the patient.

Dry Suction



Air Leak Meter

figure 14

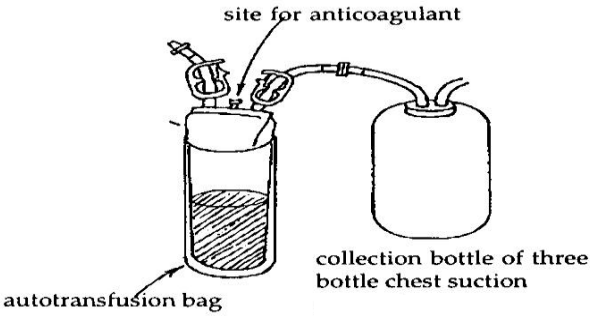

An autotransfusion attachment for thoracic blood collection.

An autotransfusion device is especially valuable in rural emergency facilities where blood is not stored in large quantities. Check with your trauma surgery consultant regarding the need for anticoagulation of the shed blood. Many trauma surgeons do not recommend anticoagulation of thoracic blood in the setting of multiple traumas because the blood is usually defibrinated by the pleural lining of the chest and will not clot anyway. Also, a fine pore blood filter, such as a 40 micron filter (Pall™ filter) is not considered necessary by most trauma surgeons when blood is desperately needed. A standard blood filter, as is present on blood administration IV tubing sets, will suffice

12. A Child Falls Through the Ice Scenario

A two-year-old child wanders onto the ice by a lake cabin. He falls through the thin ice about 15 feet from shore. About 30 minutes later he is missed and 911 is called. The child is pulled from the water limp, apneic, and without a pulse. CPR is initiated.

Upon arrival to the ED, the patient's rectal temperature is measured as 21 C. Wet clothing is removed and the body dried. A towel is placed over the scalp. A dry sheet is placed over him. The child is orotracheally intubated and heated, humidified oxygen is used to ventilate him. Two large bore IVs are established and a warm saline bolus, 20 mL/kg, is administered. An ECG strip reveals atrial fibrillation with a slow ventricular response. External rewarming is withheld because of the severe hypothermia with its threat of rewarming shock and core afterdrop. External rewarming can be implemented when the patient's core temperature reaches 30°C.

Internal rewarming techniques that can be considered:

1. Heated humidified oxygen ventilation;
2. Warm IV fluids;
3. Gastric lavage with 40º C tap water;
4. Urinary bladder lavage with sterile saline at 40º C;
5. Peritoneal lavage with sterile saline at 40º C
6. Thoracic lavage entering through a needle thoracostomy and draining out a left chest tube.
7. If available, and the patient weighs over 90 lbs. and has a BP ≥ 60 mmHg, a Level I™ fluid warmer can be used for circulatory rewarming.

Peritoneal Lavage

Peritoneal lavage can be a very effective method of core rewarming in the rural hospital. If the patient does not have a surgical scar on the abdomen, closed technique for cannula insertion can be used. If there is a surgical scar, bowel adhesions may be present and an open technique will be necessary. Other indications for an open technique are pregnancy, obesity, and the presence of a pelvic fracture. The stomach must be emptied with an orogastric tube and the urinary bladder must be drained with a urinary catheter before proceeding.

Closed Technique:

A safe technique to insert the lavage cannula into the abdominal cavity in an obtunded hypothermic patient is as follows:

1. Place two towel clips into the abdominal wall in the midline just below the umbilicus separated by one or two inches.

2. Use an Arrow ™ Peritoneal lavage kit, (available from Arrow International, Inc., Reading, PA). Attach a 6 mL syringe of saline to the 18 ga exploring needle. Fill the needle with saline and leave the syringe attached.
3. Pinch the skin and subcutaneous tissue between the two towel clips and insert the needle into it. Remove the syringe and add another drop of saline to the hub of the needle.
4. Have an assistant lift the abdominal wall with the towel clips producing negative pressure in the abdominal cavity.
5. Advance the needle through the fascia of the abdominal wall until the saline filling the needle is suddenly sucked into the abdominal cavity when the peritoneum is penetrated;
6. Insert the J tip of the guidewire through the exploring needle and into the abdominal cavity. Make a stab wound with a #11 scalpel blade through the fascia keeping the point of the blade in contact with the needle. Remove the needle;
7. Pass the 8 Fr lavage catheter over the wire into the abdomen. Attach the enclosed fluid administration set to a bag of warm saline and flush it prior to connecting it to the lavage catheter.
8. Run in the warm saline "wide open" (usually a liter in the adult and 5mL per kg in a child). Let it exchange heat with the body for a minute or two then drain it out by placing the empty bag on the floor. Repeat this until the patient's core temperature approaches 30º C, at which time external warmth can be applied.

Open Technique:
If pregnancy or the presence of a pelvic fracture is the reason for using an open technique, perform the procedure **supraumbilical**. If the reason is the presence of a surgical scar or obesity use an **infraumbilical** approach.

1. Make the incision in the midline just below or just above the umbilicus as indicated. Try to stay exactly in the midline. Any retraction has to be done very gently to avoid pulling away from the midline. Wipe fat away from the fascial layer with a sponge so that the decussating (crossed) fibers of the fascia at the linea alba can be seen.
2. Open the fascia at the linea alba with a #10 or #15 scalpel about 2 or 3 cm. If you get off of the midline you will encounter the rectus muscle making it necessary to retract it and make another incision through the posterior sheath of the rectus muscle.
3. Place towel clips through the divided edges of the linea alba and retract them. The peritoneum should now be visible. If you are using a supraumbilical approach you may encounter properitoneal fat, which you will have to push aside

4. Observe where the peritoneum is free of adhesions. Use the18 ga exploring needle to make a small hole in it. Under direct vision pass the 8 Fr lavage catheter through the peritoneum and into the abdominal cavity.
5. Use the lavage catheter as described above under closed technique.
6. When the lavage cannula is removed, the fascia should be closed with heavy suture. Close the skin with staples or suture.

Use an IV fluid warmer. The Level 1™ fluid warmer (available from Smiths Industries, Rockland, MA), is an expensive but invaluable tool in treating and preventing hypothermia.

There are **Intravascular Temperature Management (IVTM™)** devices which are expensive but can rewarm a patient quickly. The same device can also be used to cool a patient who presents in hyperthermia. IVTM™ technology manages the patient's temperature from the inside out.

A Zoll catheter is inserted into the central venous system of the patient either femoral, subclavian, or an internal jugular insertion. The Alsius Coolgard 3000® or Thermogard XP thermal regulation system controls the temperature of the saline circulating through the catheter balloons via remote sensing of the patients temperature. The patient is cooled or warmed as venous blood passes over each balloon, heat is exchanged without infusing saline into the patient.

Thoracic Lavage

Warm thoracic lavage requires that the patient have a left sided chest tube and a thoracostomy needle in place.

1. Insert a thoracostomy needle into the left upper chest at the midclavicular line over the third rib. Infuse warm saline into the chest by attaching IV tubing to the needle. Clamp the chest tube for approximately 5 minutes.
2. Attach the chest tube to constant chest suction using an autotransfusion device to capture the evacuated saline. The saline can be reinfused after warming.

13. Penetrating Chest Trauma/Pulmonary Bleeding Scenario

A young male is shot in the left chest with a deer rifle in a hunting accident. He was awake at the scene but has deteriorated and is now in shock and comatose. He is intubated and ventilated but no breath sounds are heard on the left side. A large chest tube is inserted with the return of a liter of blood immediately and continues to flow rapidly. Large bore IVs are also established and fluids result in no improvement. The chest tube is clamped but still no improvement. There is a general surgeon available who does perform thoracic surgery.

Emergency Thoracotomy

Emergency thoracotomy is a procedure performed in an all-out attempt to retrieve cardiac arrested or moribund patients who may have suffered an event or injury that is potentially reversible. When surgical backup is not available, there is no point in performing this procedure. If the patient has signs of life on arrival but is moribund, emergency thoracotomy should be performed. When the patient loses signs of life en route to the hospital, more judgment has to be used depending on the time and distance of transport, probability of an easily reversible cause (e.g., stab wound to the heart), etc.. Blunt trauma victims losing signs of life en route are probably irretrievable, but there is room for judgment here.

Thoracotomy Procedure

1. Place the left arm on an armboard; otherwise it will be inaccessible later for vascular access. Pump up the level of the cart so that it is at typical operating table level. Adjust the lighting. Prep the left chest with antiseptic solution and frame the chest with sterile towels. Then, the operator makes a skin incision starting at the lateral border of the sternum at the 4th intercostal space level and extending it to the midaxillary line across the chest just below the nipple line in males and following the reflection of the breast in females. This initial skin incision is carried down to the underlying pectoralis major muscle but not through it.
2. The pectoralis major muscle is then divided at the same level. It will contract and separate spontaneously as this is performed revealing the underlying ribs and intercostal spaces. Select the 5th intercostal space by noting the origin of the pectoralis minor muscle from the upper edge of the 5th rib laterally. Ask the person ventilating the patient to disconnect the ventilating device from the endotracheal tube so that the lung will collapse when the chest is opened.

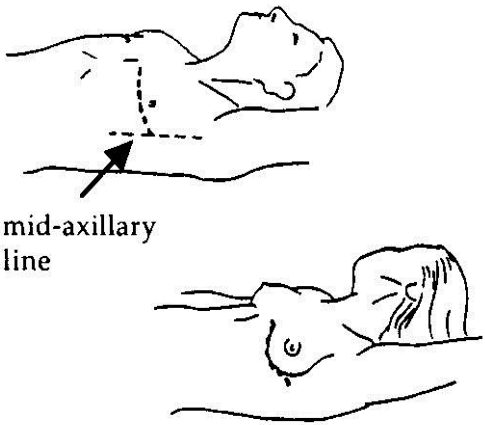

The skin incisions used in males and females

3. Use a blunt curved Mayo scissors to enter the chest over the top of the 6th rib. The lung will collapse away from the chest wall. Use the Mayo scissors to spread enough to allow you to insert a finger. Insert a finger to be sure the lung is not adherent to the chest wall. Reconnect to the ventilating device. Use the Mayo scissors to open the interspace medially near the costrochondral junction of the ribs and laterally to the midaxillary line trying to stay at the top of the 6th rib rather than on the inferior margin of the 5th rib where the intercostal blood vessels lie.

4. The incision is carried laterally to the midaxillary line. Going further posteriorly endangers the long thoracic nerve that lies near the latissimus dorsi. The medial limit of the incision should be near to the point at which the ribs change direction close to the sternum. The internal mammary artery is located underneath this junction between the cartilaginous and bony rib.

5. Insert a rib spreader and open the incision widely. Ribs will crack. Bleeding may occur from the wound edges, especially if the patient develops a blood pressure. Use a large bore sterile suction tip to evacuate blood from the thorax. If there is a lot of blood present and the autotransfusion apparatus is prepared, it can be salvaged for autotransfusion.

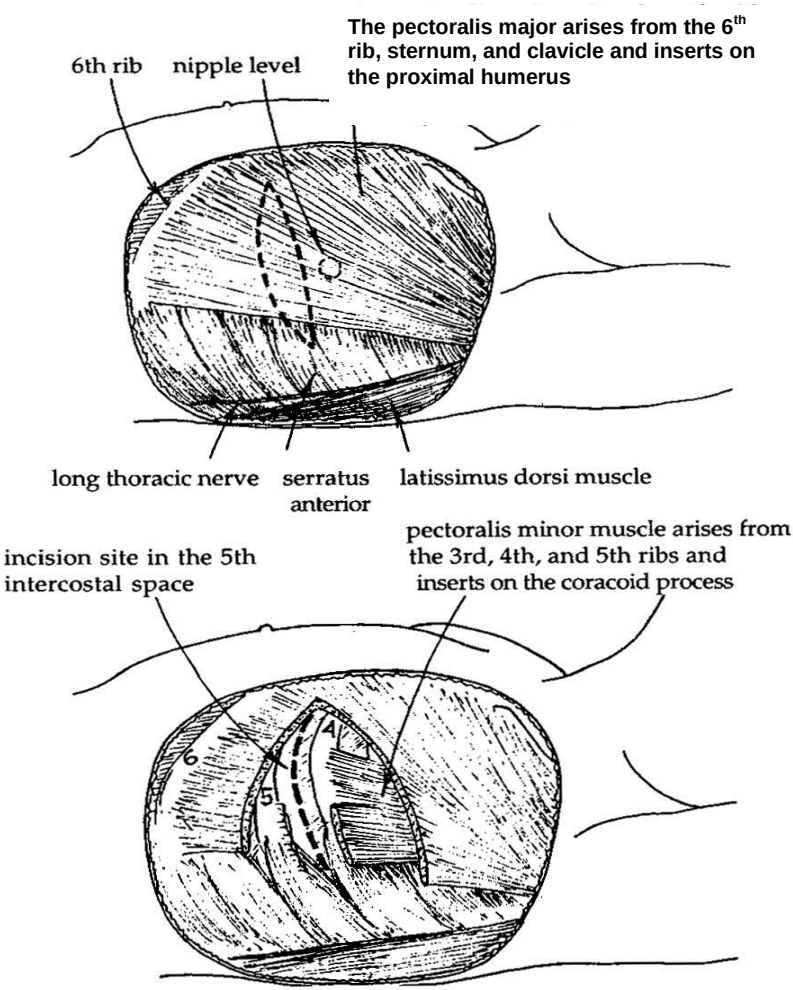

The fifth intercostal space between the fifth and sixth ribs gives the operator the best exposure for pericardiotomy and internal cardiac massage. Note how a slip of the pectorals minor arises from the fifth rib.

6. Insert a silicone tubing shod Ruiz aortic compressor (Sontec instruments, Inc., Englewood, CO) over the surface of the left diaphragm onto the vertebral column where it will compress the aorta against the spine. Cardiac output will be perfusing the heart and brain; arterial bleeding below the diaphragm will cease.

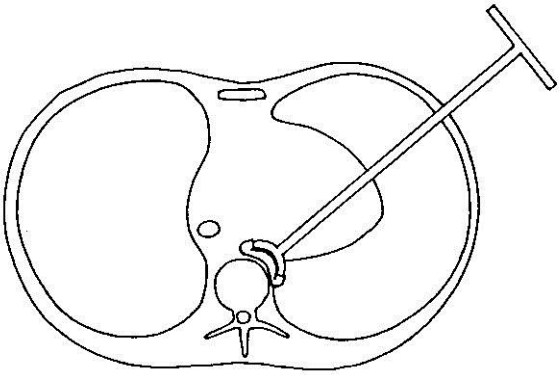

The Ruiz aortic compressor pressing the descending thoracic aorta against the vertebral column.

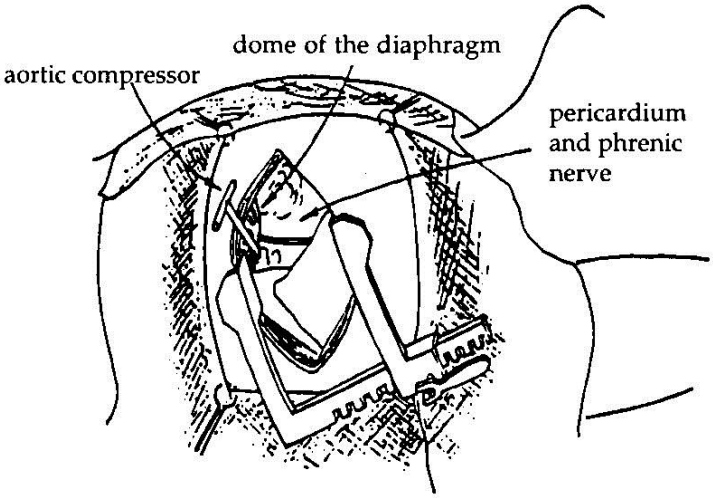

The diaphragm will be prominently seen when the chest is opened.

Compress the Hilum of the Lung

The index finger of the right hand is passed superiorly and posteriorly around the hilum of the left lung. The hilum is then pressed against the index finger with the thumb to tamponade the pulmonary vessels in the hilum, stopping or reducing the bleeding from the left lung until surgical repair can take place.

14. Stab Wound to the Chest Scenario

A young man comes in with a stab wound to the left chest. He is in shock. His neck veins are distended, muffled heart sounds are heard and hypotension are present (Beck's triad).

Identifying Heart Chambers with Ultrasound

Cardiac ultrasound for emergency management purposes is a skill that is easily attainable. A subcostal window is used to view the heart. The conditions that can be discerned are: 1) Cardiac tamponade indicated by a ring of hypoechogenicity (a black ring) around the heart; 2) Hypovolemic, neurogenic or septic shock indicated by vigorous cardiac activity in the face of hypotension; 3) Cardiogenic shock indicated by a global loss of cardiac contractility. A massive pulmonary embolus usually produces a dilated right ventricle, as can a right ventricular infarction.

Directing the probe perpendicularly will display the abdominal aorta if there is not too much gastric or bowel gas present. This is an extremely valuable tool for identifying patients with an abdominal aneurysm. A pulsatile mass is not always palpable.

Study your own machine so that you will be prepared to use it.

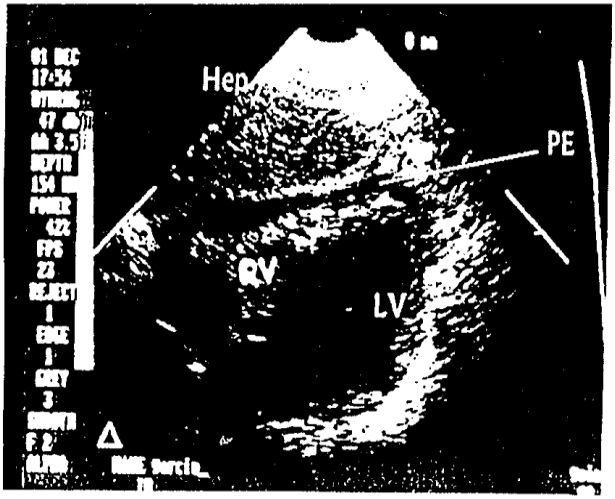

A. Pericardial effusion as seen on ultrasound through the subcostal window.
PE = pericardial effusion; LV = left ventricle; Hep = liver; RV = right ventricle. Notice the collapse of the right ventricle. Note how the effusion curves around the heart. Peritoneal fluid and pleural fluid stripes do not curve around the heart.

B. Position of the probe when using the subcostal window

Percutaneous Pericardiocentesis for Tamponade
Sheep anatomy does not allow pericardial sac puncture and cannulation as it is performed in humans. Instead, use the following procedure:

1. Apply the ultrasound probe directly to the heart over the left ventricle. This result in an image with the order of appearance of the pericardium, the right ventricle and the left ventricle reversed.
2. Produce cardiac tamponade by placing a 14 ga catheter into the pericardial sac and infusing saline. This takes about 130 mL of saline. The monitor reveals tachycardia, depressed pulse pressure and severe hypotension.
3. Repeat the ultrasound exam to show the saline layered between the heart and the pericardium. Inject the remaining 20 mL of saline demonstrating the turbulence effect on ultrasound. This effect confirms the position of the cannula in the pericardial sac.
4. Aspirate 35 mL of the saline using a large syringe. Note that the pulse pressure widens and systemic pressure rises.

Description of Pericardiocentesis as Performed in Humans

1. The pericardial effusion is identified with ultrasound as described previously.
2. The exploring needle from a percutaneous pericardiocentesis set (Wood pericardiocentesis™, available from Cook Critical Care, Bloomington, IN), is inserted next to the xiphoid process under the left costal margin directed towards the patient's left shoulder. Attach a 35 mL syringe to the needle.
3. When blood returns through the exploring needle, extract a few mL and reapply the ultrasound probe. Inject the blood back into the chest rapidly. The turbulence produced will be seen on ultrasound and positively identify the position of the needle either in the pericardial sac or the right ventricle.
4. If the needle is in the pericardial sac, remove 35 mL of blood. This will restore stroke volume to near normal and the patient will improve.
5. Insert the guidewire of the set into the pericardial sac through the needle. Before removing the needle make a stab incision with the #11 blade on the needle through the fascial layers of the abdomen.
6. Pass the dilator of the set over the wire into the pericardial sac.

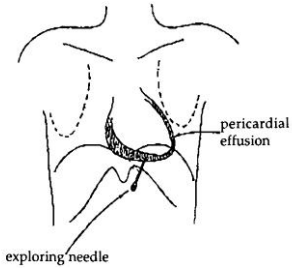

7. Remove the dilator and pass the pigtail catheter of the set over the wire into the pericardial sac. Remove the wire. Attach a stopcock and syringe for repeated aspirations of blood.

Obviously, this procedure takes time. Removing 35 mL immediately buys the time necessary to get this done.

In humans percardiocentesis should be done using this left costal approach under ultrasound guidance unless it is emergent.

When an ultrasound machine is not available, the emergency physician should use pericardiocentesis to establish the diagnosis of cardiac tamponade. The classic Beck's Triad of hypotension, distended neck veins, and muffled heart sounds are, unfortunately, not always present.

A significant mechanism of injury (penetrating chest wound or blunt chest trauma), probability of a myocardial infarction about three or four days ago, an illness suggestive of pericarditis, a probable aortic dissection, and bigeminy on ECG are other clues. A chest x-ray may reveal a globular appearance of the cardiac shadow. If the needle touches the myocardium, PVCs will result and you may feel the heart beating against the needle.

Pericardiocentesis is a temporizing measure. Repeated aspirations may be necessary before definitive surgery can take place. If the pericardiocentesis attempt fails to return blood, the blood has most likely clotted. If the patient is in mortal distress, with loss of consciousness, a thoracotomy would be needed to allow for the performance of an internal pericardiocentesis

Internal Pericardiocentesis for Clot

An 8-inch Adson dural hook is used to puncture and tent up the pericardium. The curved Mayo scissors used to open the chest is used to snip a small hole in it. The blades of the scissors are then spread to make a 1.5 cm incision in the pericardium. A sterile suction tip is used to extract clot if it does not extrude spontaneously. A finger is then used to cover the pericardial incision if tamponade is needed to control bleeding. The tamponade can be released periodically until surgical intervention can occur.

It may be unwise to open the pericardial sac widely because you may not be able to control or close the cardiac wound(s). It is better to temporize until definitive surgery can be performed. However, if the heart fibrillates or the bleeding is excessive, you will be forced to widely open the sac in order to perform effective internal massage or to attempt control of the bleeding.

In the laboratory, ventricular fibrillation is produced using a 9-volt battery applied directly to the left ventricle

Pericardiotomy and Staple Repair of Heart Wounds

If the heart is fibrillating or in asystole and pericardial tamponade is present, it makes sense to go ahead and open the pericardium to evacuate blood and clot to attempt wound closure so that effective internal massage can be conducted. Visualize the phrenic nerve as it courses over the pericardial sac posteriorly.

Grasp and tent up the pericardium with an Adson dural hook. Make a 1.5-2.0 cm incision into it with Mayo scissors. Place two fingers into the incision and tear the sac longitudinally as far as you can. This technique is used to avoid inadvertent injury to the myocardium.

The heart will now fall out of the pericardial sac. If not, insert two fingers and use sharp dissection to open the sac further. If bleeding is massive, place the index and ring finger of your left hand behind and below the heart so as to occlude the inferior and superior vena cavae. This is called the Sauerbruch grip. It reduces the inflow of blood to the heart. Suction out blood and clot to identify the bleeding site. Do not defibrillate the heart before repairing the wound.

Cardiac Stapling

If the bleeding site can be visualized, cardiac stapling may be successful. Wide skin staples are applied with a pistol grip stapler. This technique is less perilous to the operator than suture technique and much more rapid. The operator should attempt to occlude the bleeding site with a finger, then expose one end of the laceration just enough for a staple to be applied. Work the entire length of the laceration, applying a staple every 5 millimeters. Atrial as well as ventricular wounds have been closed with this technique. Avoid stapling across coronary vessels. These staples should be replaced with sutures in the operating room.

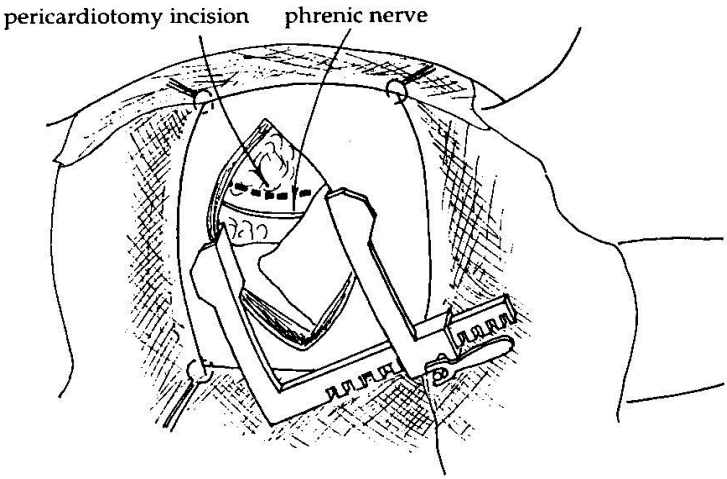

A rib spreader is used to gain exposure for pericardiotomy
The nose rotates

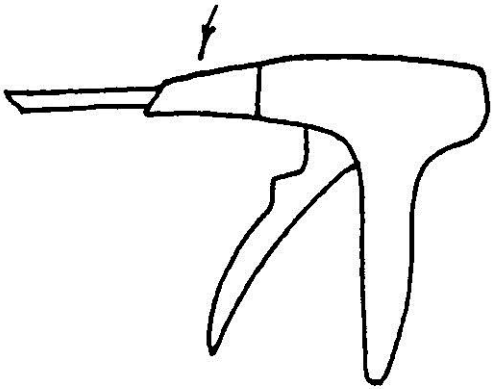

The Multifire Premium™ -35W stapler

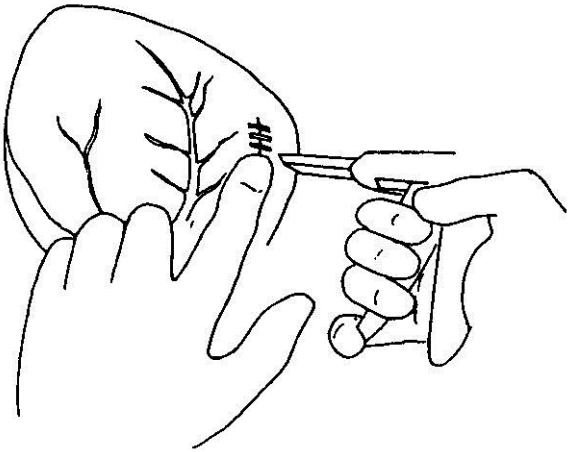

Stapling the right ventricle and atria is like stapling a tomato. Do not use pressure.

Foley Catheter

When the wound is stellate or otherwise not suitable for staple repair, a 20 Fr Foley catheter with a 30 mL balloon can help control bleeding. Fill the catheter with saline and clamp it to reduce an air embolism risk. Insert the catheter into the wound and inflate the balloon with saline. Pull the balloon gently against the heart wall to reduce bleeding. Do not pull too hard or it will pull through. Also, if you attempt stapling or suturing with it in place, temporarily push it into the ventricle to that the balloon is not ruptured.

Internal Cardiac Massage and Defibrillation

Internal cardiac massage can be conducted left-handed or right handed. Two hands can be used or, if the heart is large, it can be compressed against the sternum with one hand. Ideally, an arterial line will be inserted so that the effect of each compression can be seen. Alternatively, an O_2 saturation monitor may display a pulse. The rate of compression will depend on the rate of refill. It is very easy to puncture the myocardium with a thumb or fingertips, so be careful to use only the flat surface of your fingers. Internal defibrillation is simply a matter of compressing the heart between internal defibrillation paddles, which are placed anteriorly and posteriorly. The dose of current is 20 Joules for adults and 0.2 Joules/kg in children. If needed, up to 50 Joules can be used. Most monitors do not allow you to exceed this maximum. Intracardiac epinephrine injected into the left ventricle can coarsen fibrillation and enable defibrillation.

15. Head Injured Patient with a Herniation Syndrome Scenario

A high school football player was briefly knocked out during a game. He is brought to the emergency department where he becomes less responsive. He has weakness on the right side and his left pupil is dilated. His right toe goes up on Babinski testing. He is intubated, hyperventilated, and given IV mannitol but he does not improve. The patient has a seizure.

Skull Trephination for an Acute Epidural Hematoma

In many rural hospitals, CT scanning is readily available. If so, a quick CT scan is of great help. It identifies on which side of the head the hematoma is located and also shows if the hematoma is clotted or only partially so. Partial clotting is the usual finding, signifying active bleeding and a hematoma that can be evacuated. It also distinguishes between a subdural and an epidural. A "walk, talk and deteriorate" presentation usually means epidural, but subdurals can present this way, although rarely.

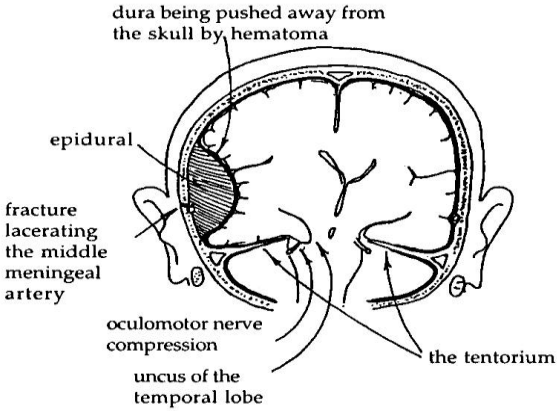

The middle meningeal artery lies between the temporal bone and the dura in a vulnerable area of the skull, just in front of the ear and above the zygomatic arch on each side. Temporal bone fractures here can lacerate the artery, which then bleeds into the potential space between the inner surface of the skull and the dura. This is an injury of young people, probably because the dura is less adherent to the skull in youth as compared to older persons. The typical patient receives a hard blow to the side of the head with loss of consciousness. The patient regains consciousness but becomes lethargic and weak on the opposite side. A pupil dilates as the 3rd cranial nerve (oculomotor) on the side of the hematoma becomes distorted by the uncus of the brain as it herniates downward through the tentorial notch. An important point is that the brain under this hematoma is usually normal, as opposed to the severely injured brain, which is frequently seen beneath a subdural hematoma.

The side selected for trephination is the side with the dilated pupil. A vertical scalp incision is made over the squamous portion of the temporal bone.

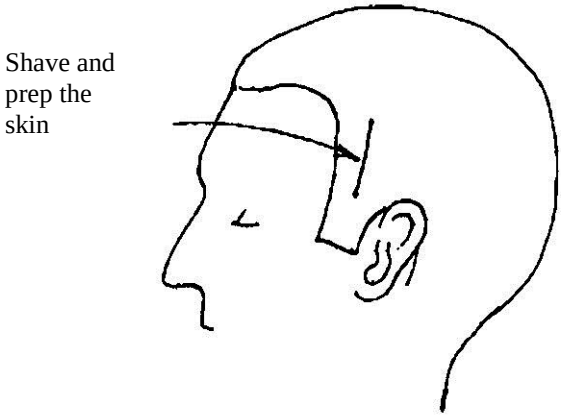

The incision will lie in the center of the sideburns and above the zygomatic arch.

Be decisive. Careful, rapid, and accurate assessment as the herniation syndrome unfolds will allow you to act at the right moment. Neurosurgical standards are that the clot must be evacuated within 15 minutes of a determination that herniation is progressing. Acute epidural hematoma injuries are uncommon but important injuries because they are reversible when managed quickly. The lucid interval between injury and deterioration means that the underlying brain is probably normal.

1. The location of the vertical incision is in the middle of the “side burns” found by placing two fingers in front of the tragus of the ear on the side of the dilated pupil. Two fingers above this point is the location of the center of the incision. Shave and prep this area. Drape off the site. Feel for the pulse of the temporal artery.
2. Make a 3-4 cm vertical skin incision centered on the identified point. Carry the incision down through the underlying temporalis muscle, avoiding the temporal artery if possible. If brisk bleeding results, use Raney clips to control it. Insert a self-retaining scalp retractor to provide exposure and hemostasis. Use a periosteal elevator to scrape the periosteum off of the skull. Expose an area about the size of a quarter (about 1 inch diameter).

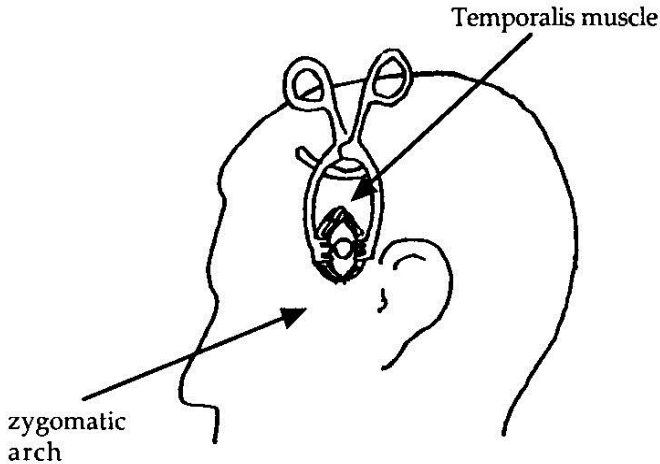

The scalp retractor provides hemostasis as well as exposure.

3. A 1/2-inch Galt trephine with a detachable handle is used. The epidural hematoma will be located on the side of the dilating pupil 80 percent of the time. An epidural hematoma can cause the opposite pupil to dilate by pushing the oculomotor nerve on that side against the tentorium. Rarely, the epidural hematoma will not be encountered by bilateral trephines as described. Raise the level of the resuscitation cart so that the patient's head is easily controlled and within easy reach. Adjust the lighting.

4. Adjust the centering point of the Galt trephine so that it protrudes about 1/8 inch. Twist the spike and the trephine into the skull. When the trephine is cutting into the skull all around its circumference, retract the spike completely and continue twisting until the trephine has penetrated 4 mm or until you feel a slight give. Remove the trephine and attempt to remove the plug of skull with small Adson pickups with teeth. Continue twisting until it is loose. Clot and blood exude from the trephine. The patient improves immediately. The plug of skull is kept sterile and sent with the patient to a tertiary center for neurosurgical definitive care. A Dandy nerve hook can be used to gently tease clot out of the trephine. Do not touch the brain. Do not apply suction. Cover the wound with a sterile dressing. IV antibiotics, such as ceftriaxone, should be given as soon as feasible. Keep the patient's head and torso up about 15 to 30 degrees if possible. Closely observe and document a any improvement in the patient' condition. If paralysis was or becomes necessary, paralysis does not affect pupil size or reactivity. Repeated Glasgow Coma Score determinations may be helpful.

The 1/2-inch Galt trephine. The centering spike is retractable. This trephine is more like a saw than a drill. You do not need to press hard to cut through the skull. The cutting portion is slightly conical so that it will not plunge into the brain.

Galt Trephine

Application of Raney Scalp Clips

Plastic Raney clips are applied to the edges of scalp wounds to stop bleeding. It is only to stop bleeding, not to close the wound, which can be done later. The clips are plastic and the applicator is a surgical instrument, which can be sterilized and reused.

Session Using a Rabbit Model

16. Newborn in Distress Scenario

A precipitous delivery of a full term infant has occurred in the ED. The child is not breathing, has central and peripheral cyanosis. You are given the responsibility for resuscitating the infant.

Evaluation and Resuscitation of the Newborn

Infants and neonates require a special resuscitation table. It should have warming lights overhead along with procedure lights. It should have an oxygen tank and oxygen flowmeter. An adjustable oxygen pressure powered vacuum bottle should also be mounted on the table for tracheal suction. A low pressure meter should be mounted on the cart that can be connected to the infant bag/valve so that transtracheal pressure can be monitored to avoid producing a pneumothorax with excessive pressure.

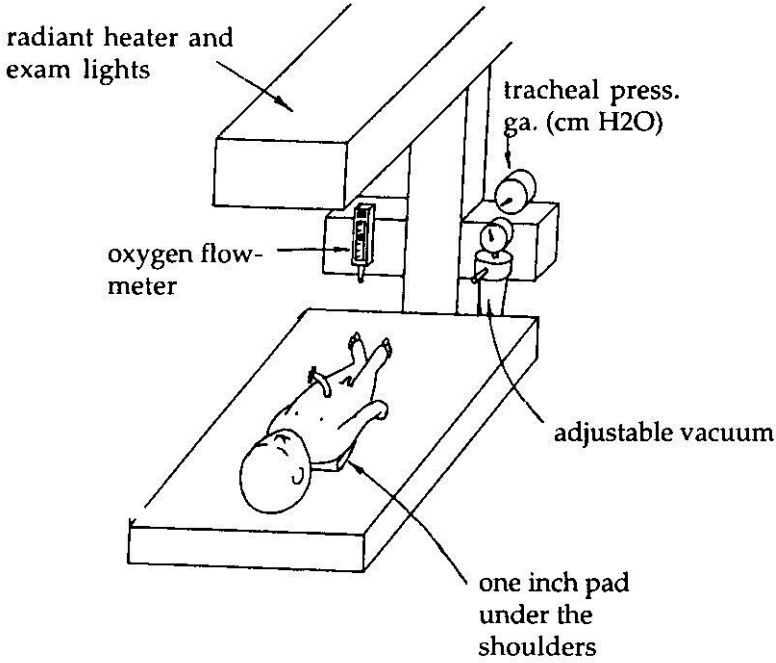

Radiant Warmer

An ideal work surface for neonatal resuscitation. Additional warmth is provided with a heated mattress (Baxter Porta-Warm™ available from Allegiance Healthcare, Albuquerque)

Overview of Neonatal Resuscitation

The Immediate Steps

1. Place and position under a radiant warmer
2. Suction the trachea if particulate meconium is present
3. Oral then nasal bulb suction
4. Dry thoroughly, remove wet linen
5. Tactile stimulation

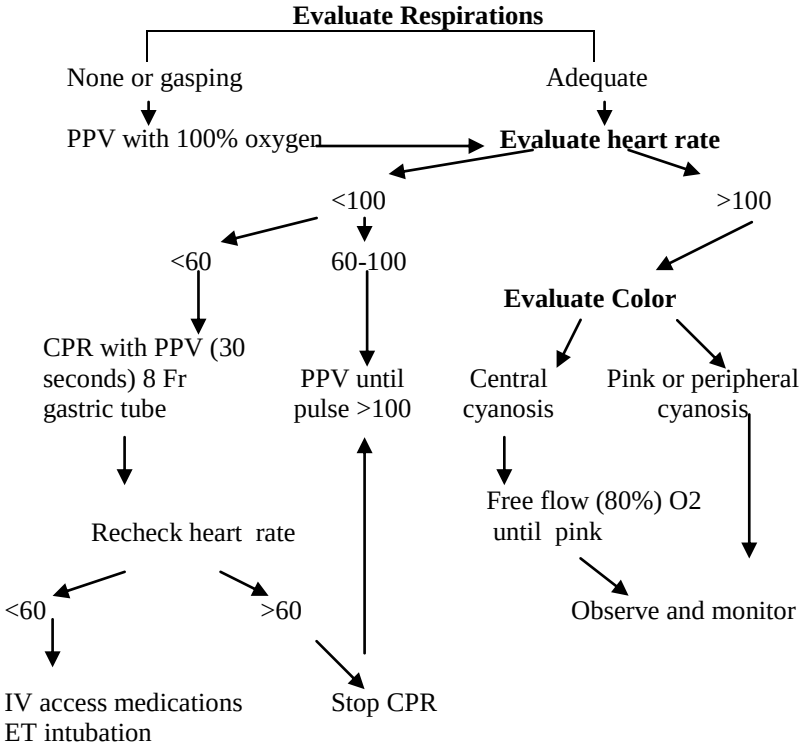

The Immediate Steps

Place the newborn infant on a heated mattress and a work surface with radiant warming lights. Do not take the time to set up the servomechanism, which automatically turns the radiant warmer off when the baby's temperature rises, this can be done later. Place the infant supine the neck slightly extended to open the airway. A folded towel or small blanket about 1 inch thick should be placed behind the baby's shoulders, but be careful to avoid over extending the neck.

If there are copious secretions coming from the mouth, turn the head to the side. Slight Trendelenburg positioning may be advantageous.

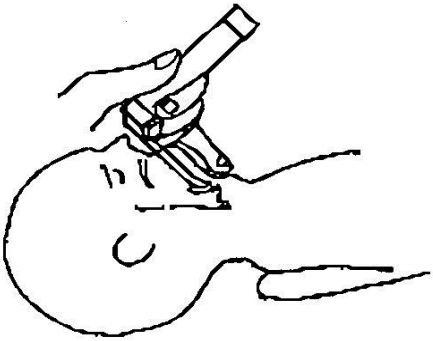

Infant Orotracheal Intubation

Unless the infant is flaccid, insert the blade into the valecula and lift the epiglottis indirectly because touching the epiglottis will stimulate gagging and laryngospasm. The little finger can be used to provide cricoid pressure. IV atropine 0.02 mg/kg with a minimum dose of 0.1 mg will help prevent bradycardia secondary to vagal stimulation with intubation. A dose of less than 0.1 mg can cause a paradoxical bradycardia.

Securing an ET Tube in an Infant

Cut a 4x4 inch square of protective see-through skin dressing (i.e. Tegaderm™) in half. Cut out a section of the dressing to result in a “pants” shape as shown.

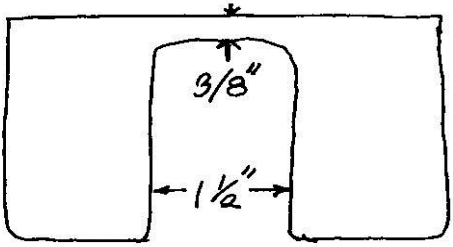

Dry off the infant’s cheeks and lips and then apply the dressing as shown.

Hold the ET tube in place by inserting a finger into the infant's mouth and press the tube against the hard palate in the midline. Now pucker the infant's mouth around the ET tube and use strips of adhesive tape to attach the tube to the protective dressing on both cheeks. The ET tube should stay in the center of the mouth or it will be pulled out of the trachea when the infant's head turns.

"Power Suctioning" for Meconium

Suction the trachea if thick, particulate meconium was present at delivery and the infant is non-vigorous. This suctioning should be done before the infant is dried because tactile stimulation may make the infant gasp in more meconium. Meconium suctioning is a team effort that has to be accomplished very quickly. This team effort should be rehearsed at every opportunity so as to maintain the team's skill.

The suction bottle on the resuscitation cart should be adjusted to 80 -100 mmHg negative pressure. Attach a length of suction tubing to the suction bottle and attach a meconium aspirator to it. This adaptor has a side hole. When a finger is placed over the side hole, suction is delivered. This adaptor will fit over an endotracheal tube.

Set out three size 3.0 ET tubes with obturators. Also set out three size 2.5 ET tubes in case the size 3 tubes are too large. The intubator visualizes the vocal cords using a laryngoscope with an infant Macintosh or Miller blade. The intubator inserts the first ET tube about 3 cm into the trachea and an assistant pulls out the obturator and attaches the meconium suction adaptor to the ET tube. The assistant then removes the ET tube with their finger over the side hole of the adaptor. The assistant also turns the ET tube while removing it.

The intubator does not withdraw; rather the intubator continues to keep the vocal cords in view. The assistant places the next ET tube in the intubator's right hand for insertion .If the heart rate remains stable, the process may be repeated until meconium is removed or the infant becomes bradycardic (heart rate decreases from 100 down to 80). This will usually take two or three aspirations. Insert an 8 Fr gastric tube through the mouth to prevent aspiration of gastric meconium.

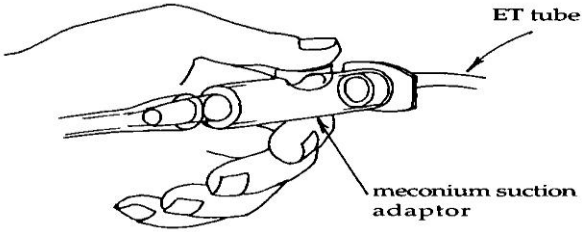

The meconium suction adaptor is a very useful tool. It can be used to extract food and balloons from the trachea in the same manner.

Oral then nasal bulb suction
The infant's first respirations will be strong gasps through the mouth before nasal breathing is established, so aspirate the mouth first. Be careful not to insert it into the posterior pharynx because this will result in bradycardia.

Dry the infant thoroughly
Remove wet linen. Use a warm dry towel. This in itself will usually provide enough tactile stimulation to initiate respirations. If the baby has not begun breathing, additional tactile stimulation can be provided by flicking or tapping the soles of the feet or by rubbing the back. If the baby does not breathe within 10 to 15 seconds, start positive pressure ventilation using a bag/valve/mask.

Evaluate respirations
If the infant is obviously gasping or not breathing, go immediately to positive pressure ventilation. When administering the baby's first breath, give one or two ventilations at 40 cm of H_2O pressure. Subsequently, the ventilations should be at no more than 20 cm of H_2O. It is very difficult to judge how much pressure is being given, so a cm of H_2O pressure gauge on the resuscitation cart should be attached to the bag/valve/mask device. There are also resuscitation bags that contain a cm of H_2O gauge. Excessive pressure will produce pneumothoraces. Ventilations should be delivered at a rate of 40-60 breaths per minute. Hypoxia in a newborn produces bradycardia, so use heart rate to help determine the need for continued positive pressure ventilation. A 500 mL bag/valve/mask is ideal for purposes of neonatal resuscitation. A 250 mL neonate bag may be inadequate.

Evaluate heart rate
If the heart rate is less than 60 bpm begin cardiac compressions while continuing positive pressure ventilations.

There are two techniques used for chest compressions in the newborn. In the thumb technique (which is the preferred technique) the thumbs are placed on the sternum just below the nipple line and the fingers encircle the chest for back support. In the two-finger technique the chest is compressed with the ring and middle finger and the other hand used to support the back. This technique is used when procedures are being that the thumb technique may interfere with.

The depth of compression should be 1/2 to 3/4 inches and the rate should be 120 bpm. It is not necessary to interrupt chest compressions for ventilations, however, if it seems more effective, use a 3:1 ratio of compressions to ventilations. This will result in 90 bpm and 30 breaths per minute for a total of 120 events.

Check heart rate every 30 seconds to determine if CPR should continue. Usually a brief application of chest compressions and bag/valve/mask ventilation will result in an improvement in heart rate. Palpate the umbilical cord for the pulse rate or listen to the heart sounds. Tap the rate on the table so that all team members are aware of it. If the heart rate is between 60 and 100 bpm, positive pressure ventilation alone is probably all that will be necessary. If the infant does not improve and the heart rate is between 60 and 80 bpm, compressions may need to be continued. Check the heart rate every 30 seconds to determine if positive pressure ventilation should continue. If the heart rate is greater than 100 bpm, the infant is doing well and no aggressive steps are necessary.

Evaluate color

Now simply observe the infant (heart rate >100 bpm and breathing well) for color. If the infant is pink or there is only cyanosis of the limbs, the infant is doing well and simple observation is all that is needed. If the infant's trunk is cyanotic, applying 80% oxygen will suffice. This is done by holding the end of an oxygen tube 1/2 inch from the baby's nose and mouth at a flow rate of 5 liters/mm. Continue this until the baby is all pink, but reapply the oxygen if cyanosis returns.

Continued bradycardia

If positive pressure ventilation with a bag/valve/mask and chest compressions do not result in a rise in heart rate within about 30 seconds, more aggressive measures will be necessary. Orotracheally intubate, ventilate, and establish IV access.

Cannulating the Umbilical Vein

Cannulate the umbilical vein with a 3.5-5 Fr umbilical catheter filled with saline. Insert the cannula just within the abdomen so that damaging the liver by injected medications is avoided. Use umbilical tape to provide hemostasis before and after the cannula is inserted.

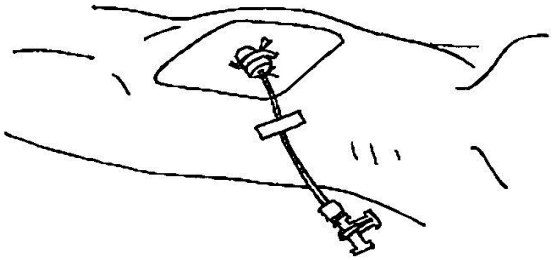

The most effective method of securing the umbilical catheter is to use a clear adhesive dressing to "plaster" the umbilicus and catheter down on the abdominal wall as shown. Use a dressing, such as Tegaderm™ or Polyskin II ™**,** which is not harmful to the baby's skin. Also suture the cannula in place either to the umbilicus or to the skin.

If IV fluid is required for the newborn, D10.45NS should be used. Volume expanders should be considered in any newborn who fails to respond to initial resuscitation. The infant could be hypovolemic because blood was sequestered in the placenta or because of blood loss from the placenta. Signs of hypovolemia in the newborn infant include pallor, weak pulse (even with a good rate), and poor response to resuscitative measures.

The three most commonly used volume expanders are:

1. Normal saline solution;
2. Ringer's lactate solution; and
3. Whole blood (O negative cross-matched with the mother's blood or with cord blood).

The fluid bolus is administered at a volume of 10 mL/kg with a syringe over 5 to 10 minutes. This can be repeated if signs of hypovolemia persist.

Use of Drugs in Neonatal Resuscitation

Epinephrine is the first medication administered. It is given at 0.1-0.3 mL/kg of a 1:10,000 solution rapidly IV or through an umbilical catheter. Epinephrine may be given down an endotracheal tube only while other access is obtained. The dose given down the ET tube is 0.3 to 1.0 mL/kg of 1:10,000 solution. Epinephrine increases the rate and strength of cardiac contractions (beta effect) and causes peripheral vasoconstriction (alpha effect). If the heart rate remains below 100, consider repeating the dose every 5 minutes as required.

Sodium bicarbonate is used for prolonged CPR and resuscitation. It is also used when there is documented acidosis. It is only effective if ventilations are effective. The adult solution is 8.4 % and contains 1 mEq/mL. Dilute this to 4.2 % with saline (0.5 mEq/mL). Alternatively, there are commercially available 10 mL syringes at 4.2 %. Administer sodium bicarbonate 2 mEq/kg IV slowly over at least 2 minutes.

Naloxone hydrochloride is a narcotic antagonist that may be indicated in neonates for the reversal of respiratory depression caused by maternal narcotic administration within 4 hours of delivery. The duration of narcotic effect may exceed that of naloxone; therefore, continued monitoring of the neonate is necessary. It can also induce narcotic withdrawal if the mother is narcotic dependent. Severe seizure activity can result; so continued respiratory support of the neonate may be preferable to reversing the narcotic. Consult a neonatologist regarding this possibility. The dosage is 0.1 mg/kg and may be repeated every 2-3 minutes as needed. Its duration of action is 1-4 hours. It can be given IV, IM or subcutaneously.

Dopamine is an adrenergic drug with mainly beta effects at low doses. It can be useful in the management of neonates who remain hypotensive after the steps described above. Consultation with a neonatologist is mandatory at this point. In preparation for transfer, a dopamine drip solution can be prepared for continuous infusion to support the neonate's blood pressure. The infusion should start at 5 µg/kg/minutes. It can be increased up to 20 µg/kg/minutes if necessary.

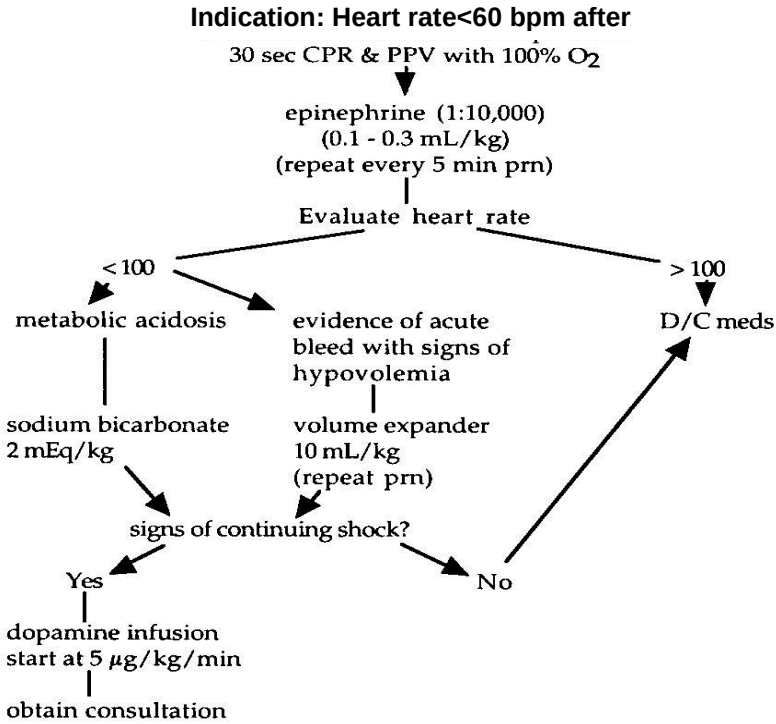

Considerations When Intubating Children

1. The size of the ET tube can be estimated by looking at the child's little finger. Specific references such as the Hennepin County Medical Center Pediatric Drug Book and the Broselow tape should be available. Here are some common ET tube sizes.

Newborn - 3.0 ET tube	5-6 years - 5.0 cuffed
6 months - 3.5	6-7 years - 5.5 cuffed
18 months - 4.0 cuffed	7-8 years - 6.0 cuffed
3-5 years - 4.5 cuffed	9-12 years - 6.5 cuffed

   Pediatric ET tubes have a black ring that should be placed at the vocal cords so to avoid right mainstem intubation.
2. The trachea is surprisingly short in infants. The length of the trachea is not proportional to that of an adult.
3. The cricoid cartilage forms the narrowest part of the airway in infants and small children. An endotracheal tube that can be inserted past the vocal cords might still be too large to get past the cricoid ring. The cricoid cartilage forms an effective seal around the endotracheal tube in children less than about 6-8 years of age, allowing the use of uncuffed ET tubes.

4. The cartilages of the larynx and trachea are soft and easily compressed by hyperextension and flexion of the neck. The trachea may also collapse around an ET tube, so the EID is not useful in children less than about 3 years of age.
5. The large occiput of an infant will hold the neck in flexion. Place a folded towel behind the shoulders to put the airway in the sniffing position.
6. When intubating children with active gag reflexes, try to avoid lifting the epiglottis with the blade.
7. Atropine, 0.02 mg/kg (0.1 mg minimum), should be given to avoid bradycardia.
8. A size 10 Fr ET tube introducer (Peds F1ex-Guide^{M}, available from Greenfield Medical Sourcing, Northborough, MA) will fit through a lubricated 4.0 ET tube.
9. Barotrauma is easily produced by positive pressure ventilation in children less than one year of age. Tidal volume is small and the respiratory rate is fast, with the result that well-meaning personnel can easily hyperinflate the lungs using mechanical devices or mouth-to-mouth breathing resulting in pneumothorax.
10. The intercostal muscles are poorly developed in infancy with the result that the infant relies on their diaphragms to breath. Gastric and abdominal distension in infants can severely interfere with respirations for this reason.

Infants are unable to sustain increased effort when the work of breathing is increased for any reason. Children in distress swallow air. Insert an orogastric tube in almost all cases as soon as possible.

Umbilical Artery and Vein Cannulation

The umbilical cord contains two arteries and a vein. As seen below, the large vein connects with the portal vein on its way to the liver and continues on to the vena cava. When an infusion catheter is inserted into the umbilical vein, it should reach just into the abdomen or all of the way to the vena cava to avoid harming the liver with injected medications.

The two small arteries course downward on the inner aspect of the abdominal wall to connect with the left and right internal iliac arteries in the pelvis. When an infusion catheter is placed in one of the arteries it should reach just above the bifurcation of the aorta or in the aorta above the diaphragm.

In an emergency situation, it is easiest and safest to cannulate the umbilical vein, placing the end of the cannula just within the abdominal wall. For longer-term use, it is best to place the end cannula in the vena cava above the liver.

An umbilical artery catheter is valuable when frequent blood gases need to be obtained and when arterial blood pressure needs to be closely monitored. It is not used for the infusion of drugs.

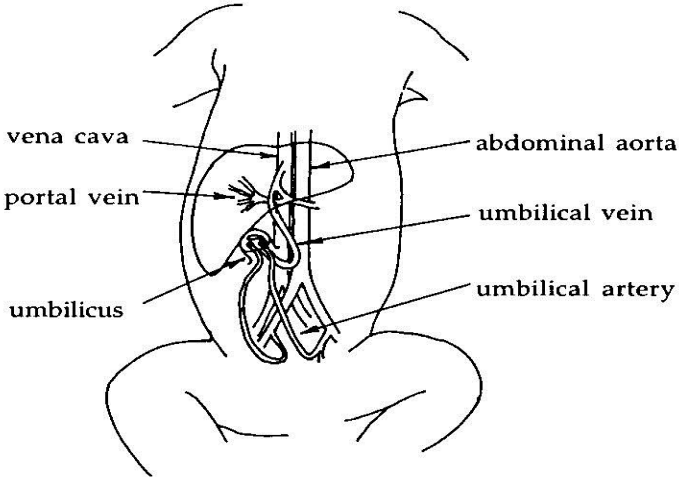

To determine the length of the venous or arterial catheter to be inserted to reach the vena cava above the liver or the aorta above the diaphragm, measure the distance between the center of a line drawn between the shoulders and the umbilicus in cm. The estimated length of catheter can now be read from a chart (check with an x-ray):

Length of catheter	in cm	Shoulder-umbilicus distance in cm	
Venous catheter	6.5	10	
	7.2	11	
	7.9	12	
	8.6	13	
	9.3	14	Add the length of the
	10.1	15	umbilical stump to
	10.8	16	these lengths
	11.5	17	
Arterial catheter	5.3	10	
	6.1	11	
	6.9	12	
	7.7	13	
	8.5	14	
	9.3	15	
	10.1	16	
	10.9	17	

Technique

Use sterile technique. Wear a mask, gloves, and gown when time allows. Prep the cord and surrounding skin with povidone solution. Place sterile towels on the field. Place an umbilical tape around the base of the umbilical cord to use as a tourniquet if bleeding occurs. Use one throw of a knot on the tape to hold it in place. Divide the cord with a scalpel or sterile scissors near the umbilical clamp. Identify the two arteries and the vein. Have an assistant hold the selected vessel for you using fine curved pickups.

Attach a three-way stopcock to the selected cannula and fill it with saline. Umbilical catheters have markings at 5 cm intervals. Use a 3.5 French catheter for an arterial line and a 5.0 French catheter for venous cannulation.

When an arterial line is inserted, slight resistance may be felt at the abdominal wall and again at the junction with the iliac artery branch. Twisting the catheter gently and applying gentle pressure or injecting 0.5 mL of 0.5 % Lidocaine to relieve spasm will usually allow successful advancement of the catheter. Insert the line to the desired length and obtain an x-ray to confirm correct placement at the T6-T10 level above the diaphragm or at the L3-L4 level just above the bifurcation of the aorta.

When a venous line is inserted, resistance may be felt as the catheter reaches its juncture with the portal vein. Gently twisting the catheter will usually allow it to reach the vena cava. Insert the line to the desired length and obtain an x-ray to confirm correct placement in the right atrium or vena cava above the diaphragm.

In the emergency situation, use the vein and insert the catheter only to 3-4 cm. Good back bleeding should be obtained if it has been inserted far enough. The catheter can be replaced with a longer one later.

17. An Infant with Tracheitis Scenario

A mother comes to the ED with her 4-month-old son. He has had a croupy cough for two days and is now worse. He also has a temperature of 105°F, is very dehydrated and listless.

The child has rib retractions and is tiring. The O_2 sat monitor reads 85% on oxygen. Your working diagnosis is croup that has progressed to tracheitis with sepsis, dehydration, hypoxia and shock. An attempt at orotracheal intubation is unsuccessful because of edema. While this attempt is made, your team has established an IO needle in the tibia. The child does not respond to the pain during this procedure. A 20 mL/kg bolus of saline is given. Dexamethasone 0.6 mg/kg is given IM. Nebulized racemic epinephrine does not seem to help.

Performing a Surgical Airway in an Infant

This child needs a tracheotomy, but tracheotomy in infants is time consuming. You elect to perform transtracheal needle ventilation as a temporizing measure.

Transtracheal Needle Ventilation (TTNV) in an Infant

1. Make a skin incision over the cricothyroid membrane area in order to accurately identify and puncture it. A midline incision is made over the thyroid cartilage and the trachea using a # 15 scalpel. This incision is carried down into the subcutaneous tissue until the thyroid cartilage and the cricoid cartilage is easily palpated with a finger. The incision is extended over the proximal trachea because the TTNV will be converted to a tracheotomy. The trachea is very mobile in infants. The cricoid cartilage is relatively large and soft with a small internal diameter. Percutaneous TTNV can be unsuccessful because the trachea is easily compressed in an anterior posterior direction by the needle. Do not hesitate to perform the puncture under direct vision.

2. The exploring needle of the TTNV set is inserted through the cricothyroid membrane. Air is aspirated through the needle confirming correct placement. The needle is angled so that the guidewire contained in the set travels down the trachea.

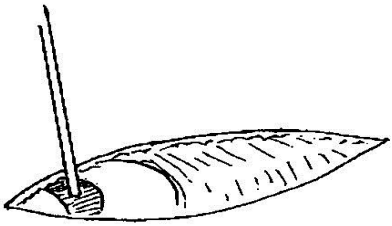

3. The needle is removed. The 6 F cannula are advanced over the guidewire into the trachea. The guidewire is removed but kept sterile for replacement later. The syringe is attached to the cannula and air is aspirated again to reconfirm correct placement

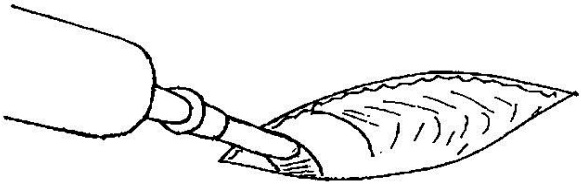

4. A modified 18 F tracheal suction catheter is connected to wall oxygen (50 psi) flowmeter. The flow rate is set at 5 L/minutes for a newborn infant and about 10 L/minutes as a starting point for older children.

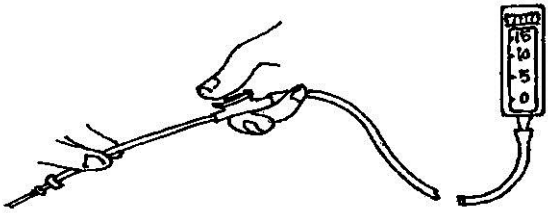

Oxygenation is achieved by plugging and unplugging the T port with your thumb. The flow rate is increased or decreased to result in rise and fall of the chest as you would expect to achieve with a bag/valve device. You must constantly hold the cannula so that it does not get inadvertently pulled out.

TTNV can be conducted for hours if need be, therefore, there is not an emergent need to go on to tracheotomy. Follow with O_2 sats and blood gases.

Conversion from TTNV to Tracheotomy

1. While ventilation with TTNV continues, use a blunt Metzenbaum dissecting curved scissors to sharply open the tissues in front of the trachea. Pick up each thin layer of tissue with pickups as shown. Use a finger to check for the presence of the trachea directly underneath. Do this frequently.

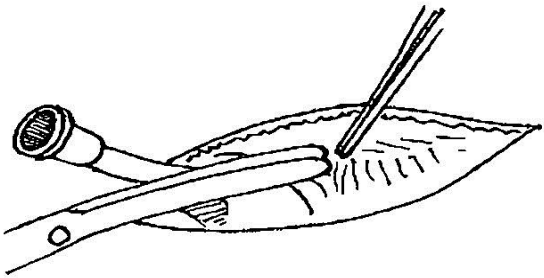

2. When the tracheal rings come into view, a 000 suture on a noncutting needle is placed around a tracheal ring on each side. These will be used as stay sutures to provide traction and to maintain ready access to the tracheotomy site.

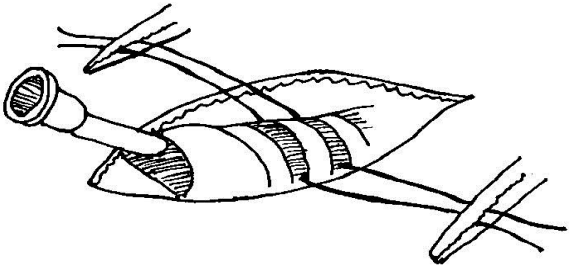

3. Reinsert the guidewire into the TTNV cannula and remove the cannula. Using the two stay sutures, pull up the trachea so that it is well seen. Now make a longitudinal incision in the trachea using a # 15 scalpel as shown dividing one or two rings.

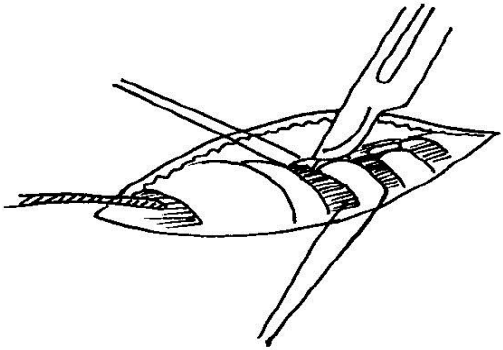

4. Insert a shortened 3.0 ET tube into the trachea as shown. Alternatively, a size 00 Shiley™ tracheotomy tube can be used. Remove the guidewire and secure the ET tube.

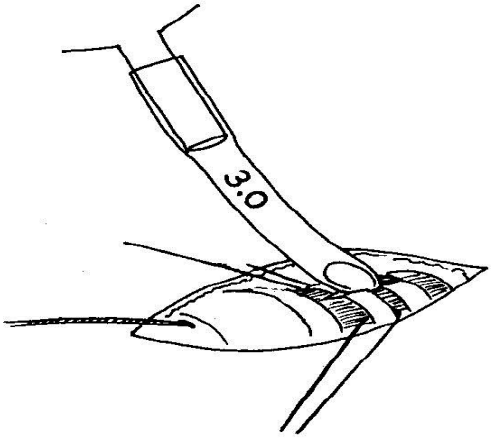

Tape the two stay sutures to the child's chest in case the airway is lost or needs revision.

Could a Tension Pneumothorax be Present?

The bronchial tree in small children is fragile and frequently injured by iatrogenic barotrauma during resuscitative efforts resulting in the development of a pneumothorax and tension pneumothorax. The mediastinum in children is very mobile and easily pushed to the side; as a result, a tension pneumothorax develops easily.

Look, listen, and feel for tracheal shift, neck vein distension, asymmetric chest motion, and an absence of breath sounds. Quickly relieve the tension by inserting a catheter over needle device into the chest at the 2nd intercostal space at the midclavicular line. An audible rush of air confirms the diagnosis.

Chest Tube Insertion in an Infant

The skin of the infant is very mobile so a skin incision can be made over the rib below the desired site of insertion. The desired site is found by drawing an imaginary line across the chest from the 5th intercostal space at the sternum. Follow this line to the mid-axillary line. A skin incision into the subcutaneous tissue is made and the skin moved up to the desired site. A mosquito clamp is used to puncture and spread into the chest.

Disconnect from positive pressure ventilation so that the lung falls away from the chest, allowing advancement of the chest tube to the apex of the chest. Reconnect to positive pressure ventilation. Secure the chest tube using the same suture technique used in adults. The amount of suction applied by the chest suction apparatus is set at 20 cm H_20 as it is in adults.

18. Obstetrical Emergencies

Precipitous Delivery
Precipitous delivery is occurring if the mother presents with bulging of the perineum or crowning of the fetal head. Place the mother on a cart and move her to a space where both mother and baby can be resuscitated if necessary. Team members should wear full precautionary gear if at all possible during delivery.

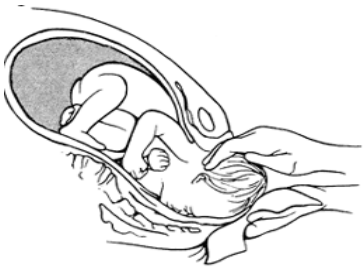

Place your palm on the newborn's head but do not hold the head in. Place a sterile towel in your hand and support the perineum.

When the head is partly out, feel the neck for a nuchal cord. If present, flip the cord over the head to free it. If it is tightly wound, divide it between clamps and unwind it.

Following active or passive head rotation, laterally place both hands on either side of the newborn's head and lower it gently to facilitate delivery of the anterior shoulder under the pubis. Suprapubic pressure by a team member may help. Now gently elevate the head while placing the infant's neck between the index finger and thumb of one hand. Slide the other hand along the infant's side and place a finger between the legs. This technique will help prevent dropping the very slippery infant.

Place a sterile clamp on the cord about 3 inches from the baby's belly. Place an umbilical clamp just proximal to the other clamp and divide the cord with a sterile scissors between the clamps. Now carefully lift the infant on to the mother's abdomen where she can help hold the infant until team members can take control. Assure that there are team members to conduct resuscitation of the baby immediately if needed.

Let the placenta spontaneously separate from the uterus. **Do not pull on the cord until the placenta is in the vagina**, because uterine inversion may result or the cord may tear. Place the placenta in a basin and inspect for completeness.

Take a tube of blood from the cord by unclamping and allowing blood to flow into the tube or aspirate with an 18 gauge needle and syringe. This blood can be used for blood typing of the infant. **After the placenta is delivered, massage the uterus** and administer 10-20 units of oxytocin IM.

If an episiotomy has been required, repair it now. Use a running absorbable suture to repair the vaginal mucosa and a subcuticular stitch of absorbable suture to repair the perineal portion. Any interrupted muscle layers should be closed with interrupted, absorbable sutures. Repair any bleeding tears that may be present .Observe the patient for continued bleeding. Insert fingers into the vagina to obtain exposure to find cervical and vaginal lacerations. Cervical lacerations can bleed heavily. Temporary control can be obtained by applying a non-crushing sponge forceps on the bleeding site until repaired. The forceps should not remain on the cervix beyond a few minutes.

Postpartum Hemorrhage

The commonest causes of postpartum hemorrhage can be remembered by **"The 4 Ts"** mnemonic developed by the ALSO course. This includes:

- **Tone: Atonic Uterus** – accounts for 70% of cases.
- **Trauma: Cervical, Vaginal, Perineal –** accounts for 20% of cases.
- **Tissue: Retained and/or Invasive Placenta –** accounts for 10% of cases.
- **Thrombin: Coagulopathies –** accounts for <1% of cases.

While the classical definition of postpartum hemorrhage is more than 500 mL of blood loss in the first 24 hours after delivery, the average blood loss in a vaginal delivery is 500 mL and in an average cesarean delivery is 1000 mL. This classic definition reflects the usual underestimation of the amount of blood loss and suggests that we should usually double our first estimate of blood loss to be more accurate. A more accurate definition of postpartum hemorrhage is the amount of blood loss sufficient to cause hemodynamic instability of the patient, a drop of hematocrit greater than 10 points, and/or the need for a transfusion.

When bleeding continues postpartum, action needs to be taken early. Summon additional help. Administer oxygen. Establish two large bore IVs. Arrange for type specific blood. Evaluate for possible cause.

Retained Placenta

Retained placenta is defined as the inability to deliver the placenta within 30 minutes after the birth. When the placenta becomes unusually adherent, the rare conditions of placenta accreta, increta, and percreta may be present. This can cause significant morbidity and mortality.

If the uterus is well contracted, the placenta is low in the uterine cavity, and the cervix and lower uterus are contracted around the placenta, the placenta is trapped. Treatment consists of applying suprapubic pressure with one hand to hold the uterus in place, and use firm traction on the umbilical cord to attempt to remove the placenta (Brandt maneuver). If this fails, treat as if the placenta has not separated.

Prepare for adequate anesthesia if manual removal is necessary. Methylergonovine (Methergine™) is not used because it induces tetanic contractions of both upper and lower segments of the uterus and is more likely to cause placental trapping.

If firm traction is not successful, manual removal is necessary. Examine the placenta and uterus. If there has been placental separation try to pull the placenta through the cervix. Relaxing the uterus can help accomplish this goal. One method of relaxation is to halt any uterine massage. Other methods include halothane general anesthetic, 0.25 mg subcutaneous terbutaline, or IV nitroglycerin. Because there is potential to lose large amounts of blood when the uterus is relaxed, this must be done quickly and you must be prepared to reverse the uterine relaxation when the placenta has been removed.

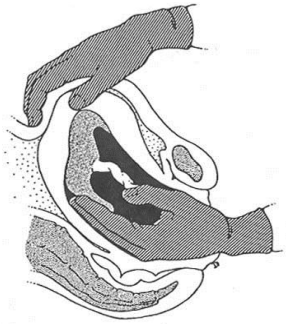

Used with permission: Human Labor and Birth, 3rd ed, Oxorn H, Foote WR, Appleton &Lange, New York, 1975.

If the placenta has not separated, identify the cleavage plane between the placenta and the uterus and slowly advance your hand along this plane. Your arm will be inserted up to the elbow. Ideally, you can deliver the placenta intact.

After removal, examine the uterus to assure complete removal of the entire placenta and membranes. Then massage the uterus, administer oxytocin, and resuscitate the patient as needed.

If you are unable to identify the cleavage plane or cannot find the cleavage plane along the entire placenta you may be dealing with a placenta accreta and a combination of manual and surgical removal may be necessary. If the bleeding is not controllable with this method an emergency hysterectomy is the treatment of choice.

Late sequelae of retained placenta are late postpartum bleeding and infection. For this reason any woman who has had treatment for retained placenta must be monitored closely.

Placenta not delivered after 30 minute

Prepare for blood loss

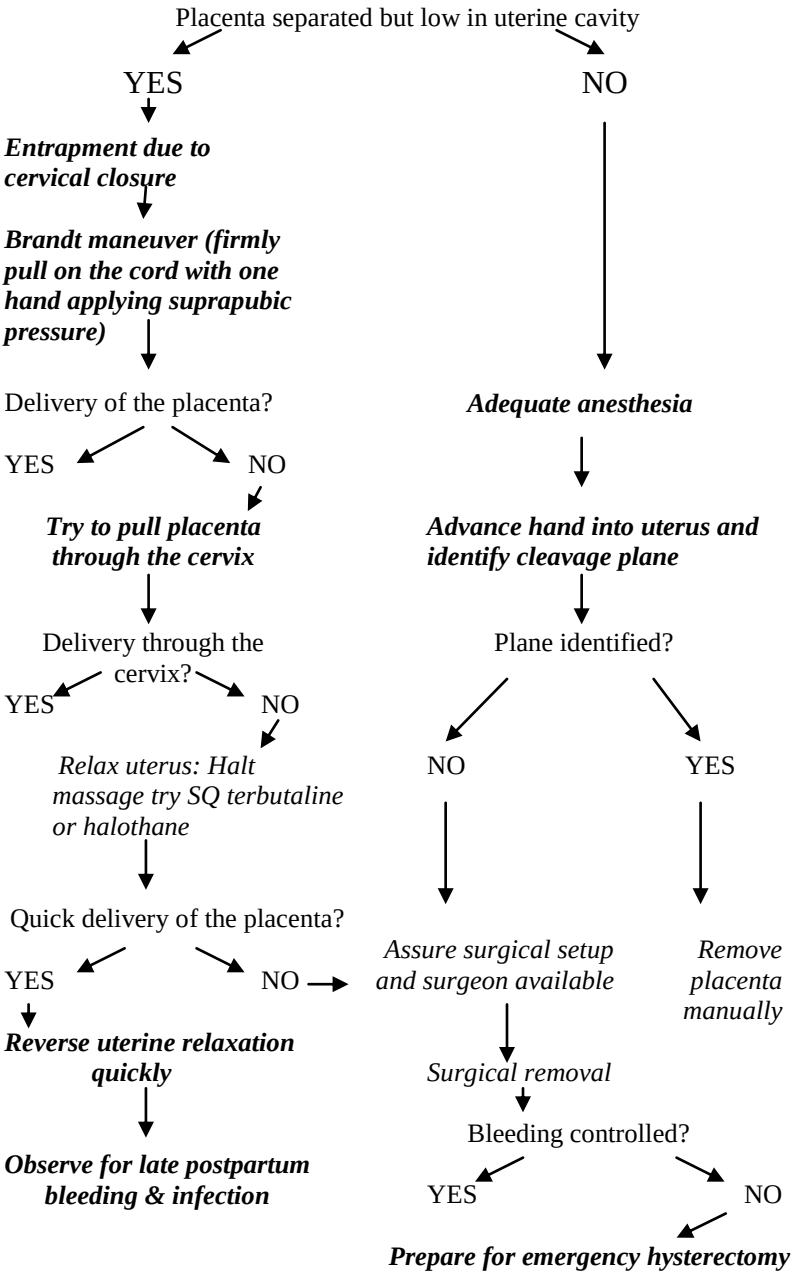

Uterine Atony

Uterine massage not only helps determine uterine atony as the cause of postpartum bleeding, it is also the first treatment used to correct the atony and stop the bleeding.

If uterine massage has not been effective, oxytocin should be given. A large bore IV is started, uterine massage is continued, and oxytocin is given either intramuscularly or by dilute IV infusion. It should not be given as an IV bolus due to possible transient vasodilatation and resulting hypotension. If bleeding persists administer methylergonovine. The usual dose is 0.2 mg IM. Again, this is not given IV. Effects from both oxytocin and methylergonovine are usually apparent within five to ten minutes of administration.

If bleeding from uterine atony persists in spite of massage, oxytocin and methylergonovine (Methergine), a prostaglandin may be used. The prostaglandin F2 alpha (Hemabate) at the dose of 0.25 mg IM or intramyometrial is often effective. Hemabate may be repeated every 15 minutes up to 8 doses but if there is not a significant improvement after two doses another method of treatment, such as 400 mcg of rectal misoprostel (Cytotec), surgical intervention, or a cause other than uterine atony should be sought.

Uterine Inversion

Precipitating factors for uterine inversion include excessive traction on the umbilical cord, uterine atony, excessive fundal pressure, placental implantation in the dome of the uterus, congenital weakness of the uterus, and primigravidity. The diagnosis of uterine inversion is made by the identification of a bluish-gray mass protruding from the vagina with or without the placenta attached. It also may be present as a vaginal mass. The importance of prompt recognition and treatment cannot be overemphasized. **Alert Nursing Staff, Physicians and Anesthesiology.**

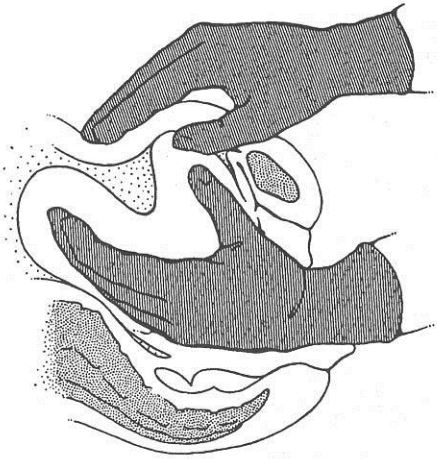

Used with permission: Human Labor and Birth, 3rd ed, Oxorn H, Foote WR, Appleton &Lange, New York, 1975.

If uterine inversion is diagnosed before the cervix forms a contraction ring around the inverted uterus, attempt to replace the uterus immediately by pushing the inverted fundus back through the cervix with your fingers. Use slow, steady pressure.

If the initial attempts at reinversion fail or a contraction ring has already formed, general anesthesia or tocolytic agents are necessary. If able to relax the contraction ring, attempt to replace the uterus. If this is unsuccessful, surgical replacement will be required. At whatever point you are able to reinvert the uterus, administer oxytocin, ergonovine, or prostaglandin F2 alpha to achieve uterine tone and prevent reinversion.

Prolapsed Cord or Footling Presentation

Cord presentation is detected by gentle vaginal examination. When the cord is discovered, avoid manipulating it. Push the infant's head up to take the pressure off of the cord. Place the mother in the knee chest position. An emergency cesarean is the treatment of choice. If obstetric resources are not available, immediately obtain obstetric consultation regarding treatment choices.

A footling presentation is also an indication for emergency cesarean section. If cesarean resources are not available, vaginal delivery may have to be attempted. See breech delivery for technical information. Obtain obstetric consultation immediately.

What is the Presenting Part?

Breech Presentation

Breech presentations can be difficult to appreciate by non-obstetricians. On vaginal exam the anus may seem to be the mouth of an infant in a face presentation. The anus, however, lies on a straight line between the sacral prominences. The mouth forms a triangle with the malar eminences.

Breech presentations are described as frank or complete. Frank breech means that the hips are flexed and the legs are extended. Complete breech means both the hips and legs are flexed.

Breech presentation is more common in preterm fetuses. As term is approached, the incidence drops to 3-4% of singleton deliveries. Factors, other than gestational age, that predisposes to breech presentation include: multiparity with uterine relaxation, hydramnios, hydrocephaly, previous breech, tumors in the pelvis, multiple gestation, oligohydraminos, anencephaly, and uterine anomalies. The diagnosis is made by abdominal palpation and vaginal exam. Conversion of breech to vertex presentation is usually attempted by the 36th week of gestation.

When a woman appears with an imminent delivery of an infant in the frank or complete breech position, the emergency physician may have to deliver the baby. There are fundamental differences between the methods of delivery in cephalic and breech presentations.

Encourage the mother not to push hard. Time for maximum dilatation of the cervix should be allowed, so slow delivery is beneficial. The fetal sacrum will either be on the right or left. The anterior hip will descend to the introitus and then, with lateral flexion of the fetal body, the posterior hip delivers over the perineum. A generous episiotomy should be made. Rotation follows delivery of the breech, allowing the infant's back to turn anteriorly. No traction should be applied. The legs are delivered by rotating the breech in the oblique diameter, inserting the index finger behind the thigh to flex the knee and pull down the leg. Rotating the breech in the opposite direction facilitates delivery of the other leg.

Delivery should proceed spontaneously until the umbilicus appears at the introitus. Traction by the operator prior to delivery of the umbilicus may promote extension of the fetal head or the development of a nuchal arm.

Delivery of the arms is accomplished by rotating the infant's body to the oblique and inserting one finger over the shoulder and following the arm to the elbow. Pressure is applied to the arm to move the elbow across the infant's chest allowing the forearm to be withdrawn. Rotation in the opposite direction allows delivery of the opposite arm. If nuchal arm exists, the infant's feet may be pulled upward and laterally over the mother's groin in the direction of the infant's ventral surface. This motion will draw the posterior shoulder over the perineum and permit delivery of the posterior arm. The anterior arm may then be delivered by depressing the body of the fetus.

The delivery of the head must now be accomplished. Keep in mind that the delivery of the head is the most hazardous and difficult part of the breech delivery and that the head must be born by flexion through the pelvis to maintain the most favorable diameters of the head relative to the pelvis. Place one hand above the fetus with the middle finger placed on the occiput and one finger on each of the fetal shoulders. The other hand is placed beneath the fetus with one finger placed on each maxilla. This helps to maintain the fetal head in flexion. The classic maneuver of inserting a finger from the lower hand into the mouth is not recommended because traction on the jaw may cause dislocation. As delivery of the head commences, an assistant applies suprapubic pressure on the fetal head to help maintain the head in flexion. The fetal body may now be wrapped in a towel to act as a sling to allow an assistant to raise the fetal body upward in a large arc. The mother is then instructed to push. Delivery assistance is provided by some traction on the shoulders applied by the delivering provider in addition to suprapubic pressure provided by the assistant. As the body of the fetus is raised through a large arc the mouth and nose appear over the perineum and finally the head emerges.

Shoulder Dystocia

Shoulder dystocia is the impaction of the anterior shoulder against the symphysis pubis after the fetal head has been delivered. It often occurs unexpectedly in normal mothers with normal pregnancies. It can occur to women who appear in the emergency department with a precipitous delivery. Shoulder dystocia is a life-threatening emergency for the fetus and needs to be recognized and treated quickly to avoid morbidity or even mortality. The problem manifests itself with the "turtle sign." The turtle sign is seen when the fetal head delivers with a contraction, then is pulled back into the vagina as the contraction ends.

Treatment

Have a protocol established that can be activated quickly. Alert nursing staff, emergency physicians, obstetricians, anesthesiologists, respiratory therapy and pediatricians according to the availability of personnel in the community. The patient and her family should be prepared for a difficult delivery. Have the patient empty her bladder. Prepare the bed and remove unnecessary items from the area to allow for equipment and personnel.

The team leader should direct activities, much like running a cardiac arrest code. Time intervals should be monitored and recorded by team member.

The pH of the neonate drops 0.04 per minute and will decrease by 0.28 in 7 minutes making the baby extremely difficult to resuscitate. For the clinician managing the delivery, it is important to know what not to do as well as what to do. Maneuvers such as initial fundal pressure and excessive traction waste time and can contribute to morbidity. The team leader must be aware of the time elapsing.

The suggested length of time spent on any one procedure to reduce shoulder dystocia is outlined in the text, but is only meant to serve as a guideline. Two or more maneuvers can be employed simultaneously.

Use the mnemonic **HELPERR** as a guide.

H – Call for HELP. You will need additional equipment and people.

E –Consider **Episiotomy** (30 seconds). Many maneuvers require getting one's hand into the vagina beside the baby.

L – Legs: Use the McRoberts Maneuver (60 seconds). Flex the mother's thighs onto the abdomen. This position simulates the advantages of a squatting position, increasing the inlet diameter. It also straightens the lumbosacral lordosis, removing the sacral promontory as an obstruction. Simultaneously this position lifts the fetus and flexes the fetal spine, pushing the posterior shoulder over the sacrum. The direction of the maternal force in this position is perpendicular to the plane of the inlet. When successful, this procedure will allow the posterior shoulder to cross the inlet and cause the release of the inward pressure on the fetal head. If the McRoberts Maneuver fails, go quickly to the next procedure, continue to hold the patient in the squatting position.

P – Pressure: Apply external-manual (30 seconds) pressure (Rubin Maneuver). Apply pressure over the suprapubic area with a "CPR" hand over the anterior shoulder, forcing it in the direction that the fetus is facing (anterior to the fetal trunk). This can be done in a rocking motion. Simultaneously, traction should be continued by the delivering clinician.

If this fails, quickly move to the next procedure.

E – Enter: Perform internal traction rotation (30 seconds) known as the Screw Principle of Woods. This involves adduction of the most accessible shoulder while traction and anterior pressure are continued. This is done using two fingers of an internal hand, usually in front of the posterior shoulder, to rotate the baby 180 degrees, thereby delivering the posterior shoulder (now anterior and the head rotated 180 degrees). Now the posterior shoulder (formerly the anterior shoulder) is turned in the opposite direction, resulting in the delivery of the shoulder and arm that was posterior in the beginning.

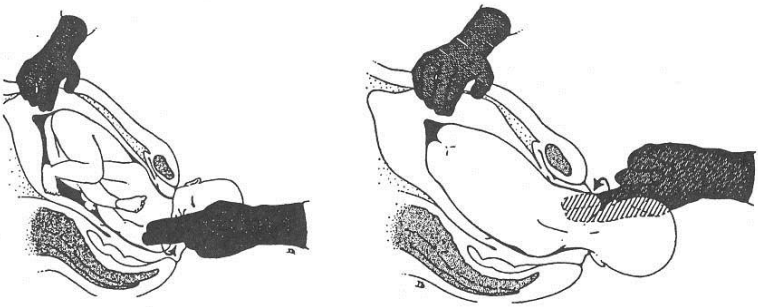

Fingers being used to rotate the posterior shoulder to the anterior position.

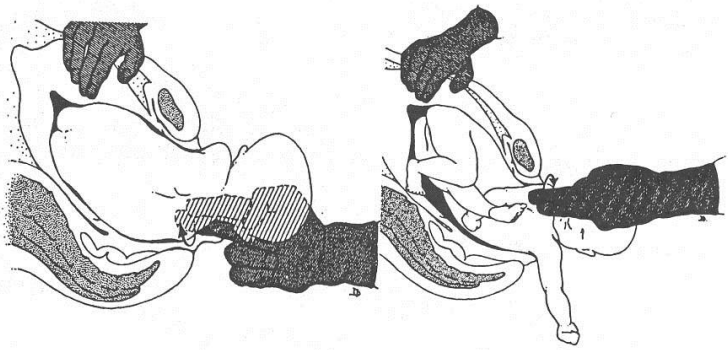

The anterior shoulder, now posterior is turned in the opposite direction resulting in the delivery of the posterior shoulder.

The Screw principle of Woods

Used with permission: Human Labor and Birth, 3rd ed, Oxorn H, Foote WR, Appleton &Lange, New York, 1975.

If delivery is still not possible, continue to the next maneuver.

R – Remove the arm. Insert a hand into the vagina behind the posterior shoulder and use two fingers to push the arm across the ventral surface of the baby and hooking the upper arm with a finger to pull it out of the vagina. This allows delivery of the anterior shoulder. If not, rotate the baby 180 degrees and repeat the maneuver.

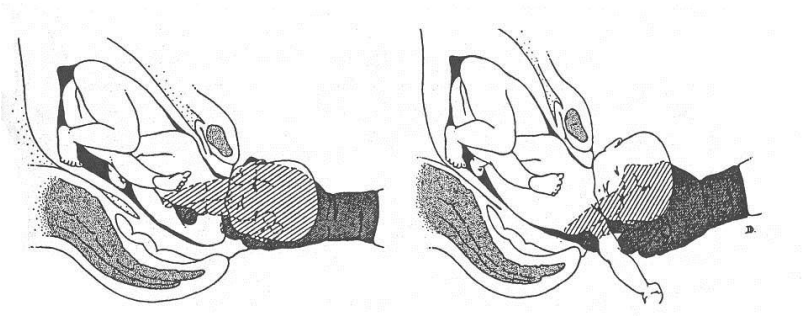

Used with permission: Human Labor and Birth, 3rd ed, Oxorn H, Foote WR, Appleton &Lange, New York, 1975.

Extract the posterior arm and shoulder by swinging it across the chest.

R - Roll the mother. At some point in this process, it may help to put the mother on her hands and knees. This simulates the squatting position even more than the McRoberts Maneuver and may afford an additional advantage.

If all else fails, any one of these maneuvers can be tried a second time. Finally, the **Zavenelli Maneuver** (cephalic replacement into the uterus and cesarean) section has been successfully performed in many cases.

Emergency Cesarean Section

The American Heart Association's Guidelines for Advanced Cardiac Life Support recommend emergency cesarean for pregnant women in cardiac arrest who are near term and have not been resuscitated within four to five minutes of arrest. Pregnant women who are moribund from trauma and are near term are also candidates for emergency cesarean section in the emergency department. When the top of the uterus is about midway between the umbilicus and the xiphoid process, fetal viability is probable. The uterus reaches this size in about 23-32 weeks, continues upward until about 36 weeks, then drops back to this level when the head is engaged in

the pelvis. The fetal weight is at least about 500 mg at viability under the most favorable circumstances. A fetal weight of 1 kg and a length of about 9-10 inches are probably more realistic. Fetal viability is improved if the procedure is performed immediately after the mother's death. However, survival is fair 15 minutes later and there is still a chance at 20 minutes, depending on the mother's demise.

1. Using a # 21 or # 10 scalpel, make a long midline abdominal incision Starting just below the xyphoid process and down almost to the pubis. Expose the fascia just below the umbilicus and incise it. Open the fascia, properitoneal fat and peritoneum using heavy straight Mayo scissors.
2. With a # 10 scalpel, open the wall of the uterus, exposing the fetal membranes or the fetus. Amniotic fluid will flood out of the uterus when the fetal sac is entered. Insert fingers in the uterus and open it longitudinally with a bandage scissors.
3. With the edge of your palm, scoop out the baby. If the head is engaged in the pelvis, use the Wigand-Martin maneuver (fingers in the mouth and on the malar prominences) of breech delivery to deliver the head out of the pelvis.

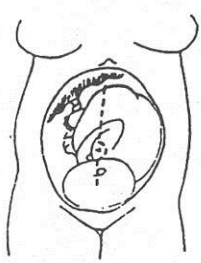

Someone may need to push the baby's head by inserting a hand in the vagina. Divide the cord about 4-6 inches from the baby's abdomen and hand off the baby for resuscitation.

4. Deliver the placenta in a similar fashion. Close the uterus with two running sutures of 00 absorbable suture or chromic suture. Approximate the abdominal wound edges using towel clips pending surgical exploration and lavage if the mother survives.

19. Loss of Vision after blunt orbital trauma

A 23 yo man is struck with a fist in the right eye. Several hours later he complains of loss of vision in the affected eye. Exam shows proptosis elevated intra-ocular pressure and an afferent pupillary defect. Vision is limited to light perception only. An orbital CT scan shows an expanding retro-orbital hematoma.

Lateral Orbital Canthotomy and Cantholysis (LCC)

Tools Needed:
Local anesthetic with epinephrine, a hemostat, forceps, and an iris scissors.

Procedure:

1. Clear debris and secretions away from around the lateral canthus and prep the surrounding skin with normal saline to improve visualization and reduce the risk of infection. If the patient is awake, an assistant should stabilize the head and maintain cervical immobilization. Although LCC is no more painful than laceration repair, it can be visually disturbing for the patient, especially if confused.
2. Inject 1-2 cc of 1%-2% lidocaine with epinephrine into the lateral canthus. This provides both pain relief and hemostasis at the time of devascularization and incision.
3. Apply a hemostat or needle driver from the lateral canthus towards the bony orbit to devascularize the area for 30-90 seconds.
4. Remove the devascularizing instrument and cut the demarcated area laterally 1-2 cm in length.
5. Using the forceps, pull the lower lid down to visualize the inferior lateral canthal tendon and cut through this tendon.
6. After the inferior canthal tendon has been cut, reassess intraocular pressure with a tonometer. If IOP remains >40 mm Hg, then decompression is inadequate. Lift the upper lid and also sever the superior lateral canthal tendon.

Complications: As with any other minor surgical procedure, there is a risk of infection and hemorrhage, as well as mechanical injury of the globe. These complications are rare and respond to therapy, while prolonged retinal ischemia does not. Lateral canthotomy wounds heal well without suturing or significant scarring.

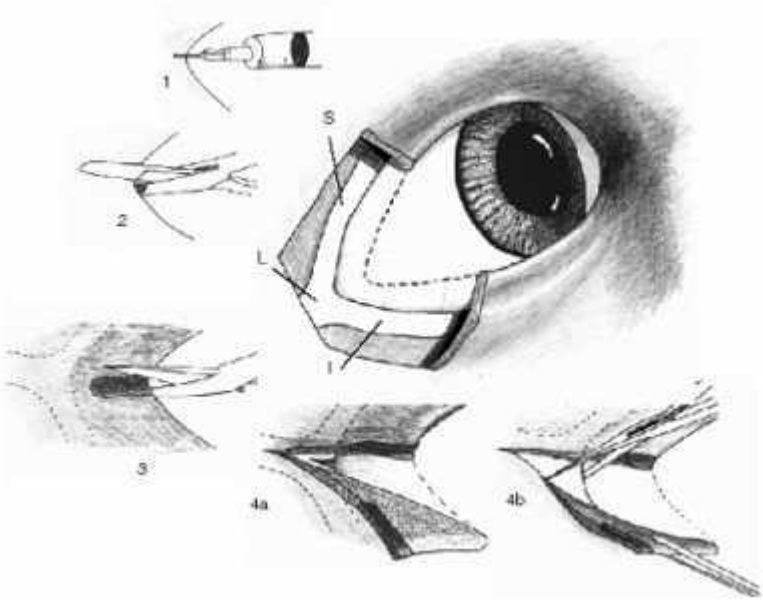

Anatomy of the lateral canthus.
I = inferior canthal tendon.
L = lateral canthal tendon.
S = superior canthal tendon.

Stages of the procedure:
1: Infiltration of the local anesthetic.
2: Devascularization.
3: Cut through skin and lateral canthus.
4a: Expose the inferiolateral canthal tendon.
4b: Cut inferior canthal tendon.

CJEM 2002;4(1):49-52 Figure3 Lateral CanthotomyandCantholysis
Used with permission.

Appendix 1

Equipment on the Emergency Airway Cart

Adult Surface and Shelf

ET tubes sizes 6 through 8 I.D. with stylets
Twill tape/ET tube holders
ET tube introducer, 15 Fr
Oral and nasal airways
Esophageal intubation detector
Bag/valve/mask device
Two laryngoscope handles
Welch-Allyn-Miller 680x blades, sizes 2, 3, 4
Macintosh blades, sizes 2, 3, 4
4 % Lidocaine tracheal spray
Phenylephrine solution
Meconium aspiration adaptor
12 mL syringes
Trauma scissors
Bite blocks
Protective eyewear
CO_2 detectors
Assorted masks
Magill forceps
Lubricant
Sponges

Pediatric Surface and Shelf

ET tubes sizes 2.5 through 3.5 I.D. without cuffs and with stylets
ET tubes sized 4.0 through 7.0 I.D. with cuffs and with stylets
Neonate, infant, toddler, and child sized masks
A 500 cc resuscitator bag/valve/mask with safety pop-off valve and cm H_2O pressure gauge
ET tube introducers, 10 Fr, 15 Fr
Infant and child Macintosh blades
#00, #1, and #2 Miller laryngoscope blades
Esophageal intubation detector
Two laryngoscope handles
Twill tape/ET tube holders
Meconium aspiration adaptors
Duoderm™/adhesive tape
Magill forceps
Oral and nasal airways
CO_2 detectors
Protective eyewear
Lubricant

Shared Shelves

Cricothyrotomy/tracheotomy tray
Transtracheal needle ventilation kits
Intubating LMA/ Non-intubating LMA
Retrograde intubation kit
Light-guided intubator
Combitube, 4 ft and 5 ft sizes
Orogastric tubes/catheter tip syringes

Equipment that will be inserted into the patient's nose or mouth must be kept clean. When the doors of the cart are opened, during patient care, all equipment that has been touched is considered contaminated and must be

cleaned or replaced to prevent spread of infection. One way to prevent all items from being contaminated is to place the items (i.e. largynscope blades/handles into plastic bags and then just the bag needs to be changed).

The emergency airway cart consists of two major pieces: the airway board; and a utility cart on which the board rests. The airway board has clear plastic doors that enable the display of equipment unpackaged and ready for use. The equipment is kept free of dust and soilage. The doors incorporate hinges that are held by breakaway locks as used on crash carts to indicate when they have been open. The board is 30w x 24d x 24h in inches and weighs about 49 lbs. The cart is Rubbermaid™ , 37 inches in height, open sides 40 x 20 and shelf clearance 13 ¼ inches. It is available from the CALS Program (calsprogramprogram.org). The board and cart can be purchased together or separately.